

## Management of abdominal Non-Hodgkin's lymphoma in children in Mosel

Osama Esmael\*, Kais Alwattar\*, Fawzi S. Shehab Aljomaily\*\*

\*Dept. of surgery, College of Medicine Mosul university

\*\*Dept. of surgery, College of Medicine, Tikrit university.

### Abstract

A Case series study include 34 child with abdominal NHL treated in AL- Khanssa teaching hospital in Mosel between January 2001 and January 2010 . 34 children with abdominal NHL treated ,complete history and full examination done, with investigations which include hematological and radiological study. Fine needle aspiration cytology from the abdominal mass done in some patient. For those patients underwent laparotomy, a uniform policy was made to resect the tumor if possible or to debulk the tumor irrespective to the diseases spread, and if this was not possible to perform only a biopsy .The resected specimen sent for histopathology. All patients send for chemotherapy. The total number was 34 patients, 25 male, 9 female. Male to female ratio is 2.8 / 1. Age ranges between 2 and 14 years, in eight patients FNA cytology done, Six out of 34 presented with acute abdomen three patients had intestinal obstruction. One patient present with multiple abdominal mass. Twenty-eight patients presented with palpable abdominal mass or masses without acute symptoms. Burkett's lymphomas are the most common type of abdominal NHL makes 30 patients (90%), Lymphoblastic lymphoma (LBL) three patients (8%), and Large cell lymphoma (LCL) one patient (2%).

### Introduction

Malignant lymphomas result from chromosomal alterations permitting uncontrolled growth of cells of lymphoid origin (1).

In 1832, Hodgkin described the gross anatomic characteristics of Hodgkin's disease. The establishment of histopathological diagnosis in the early part of the twentieth century, Hodgkin's disease (HD) was recognized and differentiated from other types of lymphomas and at this time Non-Hodgkin's Lymphomas (NHL) were defined as those malignancies of lymphoid tissue not fulfilling the histopathologic criteria for (HD) (2) .

Both types of lymphomas typically present with enlarged lymph nodes and may have systemic symptoms of fever and fatigue, extra lymphatic spread or both, However, these two types of lymphomas also have clear differences, (HD) typically present as an indolent process where as (NHL) most often presents with symptoms of rapid onset. Due to rapid tumor growth children with NHL often have associated

anatomic and metabolic morbidity of such a degree that diagnosis and treatment constitutes a medical emergency. (1)

Abdominal NHL is the most common intestinal neoplasm under the age of 10 years (2). It is more common in male in a ratio of 2:1 (3). There are two peaks in occurrence of NHL at 6 to 7-years of age and again at 12 to 14 years (2,3)

Burkitt's lymphoma was first described in 1958 as a fast growing sarcoma involving the jaw in African children; it generally affects the intraabdominal organs in non-endemic areas, where it is called American Burkitt's lymphoma. (3, 4)

### Classification: -

Revised European American classification of lymphoid neoplasm's (REAL classification) has been proposed by the international lymphoma study Group (ILSG). , This approach to NHL categorization attempts to define the diseases recognized with currently available morphologic, immunologic and genetic techniques

1-Small non cleaved cell (SNCCCL) Burkitt

lymphoma.

2-Lymphoblastic lymphoma (LBL)

3-Large cell lymphoma (LCL) (1, 4, 15)

### Patients and methods

Case series study include 34 child with abdominal NHL treated in AL-Khanssa teaching hospital between (January 2001 and October 2005) and followed till January 2010 .

Information about every patient was recorded in a special formula this information included age, sex, chief complaint and duration, , family history, each patient examined for general condition, systemic examination and examined for signs of extra abdominal NHL.

The patient investigations included complete blood picture (CBP) and ESR, B. urea, liver function test serum electrolyte, uric acid.. Radiological investigation, include U/S, Ba - study , CXR and CT -scan or MRI when available .

Fine needle aspiration cytology from the abdominal mass done in some patient.

For those patients underwent laparotomy, a uniform policy was made to resect the tumor if possible or to debulk the tumor irrespective to the diseases spread , and if this was not possible to perform only a biopsy .the resected speicement sent for histopathology.

. All patients, except one who died postoperatively, were send for chemotherapy, those patients with SNCCL (Burkit)received six cycle of 3 weeks interval modified Ziegler regime which include cytosine arabinoside (cytosar)100/m2 I.V(day1-4) cyclophosphamide 600/ m2 I.V (day 1) , vincristine, 1.4mg/m2(day1-4)and dexamethazone 0.4mg/kg/day(day1-4).

Those patients with LBL and LCL receive COMP regime. The follow up periods range between (2-5 years).

### Results

The total number was 34 patients,25 male, 9 female . Male to female ratio is 2.8 / 1 . Age ranges between 2 and 14 years , and 24 patients(75 %) presented between 3 and 5 years of age (fig 1) . Ultrasound done in all patients, except two in whom the preliminary diagnosis was appendicitis.

Ultrasound gave information about the site , size and echogenecity , but , in four patients it did not give the accurate tumors origin, in those patients the real origin was the terminal ileum (Proved during laparotomy ) ultrasonographer reported the origin from the ovary in two patients , kidney one patient and suprarenal in one patient.

CT - scan and MRI done in five patients only because of limited availability, this investigation gave good information about the mass site , size , and relation to other organs.

In eight patients FNA cytology done we could reach the diagnosis of NHL and it's subtypes in four only while in the other 4 the result was the tumor of round blue cells type therefore we precede with laparotomy.

Six out of 34 presented with acute abdomen ,two of them as a cases of appendicitis, both of them had tumor localized to the ileocecal region , underwent right hemicolecotomy .Three patients had intestinal obstruction, on exploration proved to have intussusceptions , in two of them the tumor was completely excised, the third one the tumor was not excised and debulking done.One patient presented with , intestinal obstruction with multiple abdominal masses , on exploration there was short segment of terminal ileum obstructed by tumor obliterating its lumen debulking done by excising this segment with end to end anastomosis.

Twenty-eight patients presented with palpable abdominal mass or masses without acute symptoms (fig 2).four of them diagnosed by FNA cytology and twenty four

patients underwent laparotomy , no complete excision in this group ,debulking done in 18 patients and inscional biopsy in 6.

Twenty five patients had Burkitts lymphoma and three had lymphoblastic lymphoma .

Three patients in whom the tumor sites was the ovary , ovaries and right kidney , liver and mesentery respectively , all other patients the tumors sites were the ileocecal region and / or small bowel , with mesenteric involvement .

. Burkitts lymphomas are the most common type of abdominal NHL makes 30 patients(90%)LBL3 patients(8%) and LCL one patient (2%).

One case of death before starting chemotherapy the child died one month after the operation from the complications of tumor lysis syndrome and after two session of dialysis . Three cases of relapse all relapse occurred during the first 8 months two underwent another laparotomy and debulking while the third one died from extensive disease . Two patients with abdominal mass and jaw and maxillary masses and one patient with abdominal mass and orbital involvement all of them died .

The best survival was in those presented with acute abdomen 80%,while those diagnosed by FNA cytology or biopsy without resection the survival rate was 40%,and those underwent depulking the survival rate was 66%.

### **Discussion**

In this study there is more male predomination in a proportion a proximally of 3/1 while in other series a male to female ratio is 2:1 (9).

The majority of our patients 75 % were between the age of 3-5 years which is similar to that reported in the African or the endemic type of Burkitts lymphoma, but different from the American studies where the patients presented with a higher mean age (10,12).

In this study Burkitts lymphomas is the most common type of intraabdominal non- - Hodgkin lymphoma makes 90 % LBL 8 % and LCL 2 % . While in other study Burkitts makes 56 % of all pediatric abdominal NHL , LCL 25% and LBL 3% this may be result from war (11)

In this study patients with acute abdomen were six they underwent emergency surgery four of these patients undergo complete tumor resection , often with a simple bowel resection . All of them survived; this finding is similar to that of Kemeny et al who reported improved survival inpatients with curative resections (12,13). The overall survival of the emergency group was 80% .this finding is similar to Latif *et al* who reported improved survival in the emergency group, this may be due to early presentation which makes resection easier.(13,14)

The second form presented with an abdominal mass, which is often involved multiple intraabdominal organs which makes total resection hazardous or impossible in this study , debulking done in 18 patients the survived 12 ( survival rate = 66%) while 10 cases with late presentation diagnosed by other ways (FNA or open biopsy ) only 4 of them are survived( survival rate 40% ) , this finding is different from that of Kemeny etal who suggested that the presence of extensive abdominal involvement, debulking procedure offers no advantage in terms of response to subsequent chemotherapy(13,15).

These differences may be due that most of patients with biopsy had extensive disease at presentation .

### **Conclusion:-**

1-Burkitts lymphoma makes 90% of intraabdominal NHL

2-The best prognosis was in the emergency group, these patients usually have localized disease which makes total resection easier

3-The survival rate for those patients underwent debulking was 66%,

## Management of abdominal Non-Hodgkin's lymphoma in children in mosel

while the survival rate for those with biopsy or FNA alone was 40%, we concluded that debulking still play a role in the management of unresectable intraabdominal NHL with shortage of chemotherapy.

### References

1. Keith W. Aschcraft, MD. Pediatric surgery, Third edition, W.B. Saunders, 2000: 927-941.
2. RCG. Russell, MS, *et al.* short practice of surgery, 3rd edition. London, Arnold, 2000: 155.
3. John G. Roffenaperger, MD. Swansons pediatric surgery, fifth edition, Appleton, and Lance, 1990: 431-436.
4. Abbasoglu *et al.*, intra abdominal Burkitts Lymphoma. European Journal of pediatric surgery volume 13: 217-288.
5. Richard E. Behrmar. Nelson textbook of pediatric, W.B Saunders 2002:1550-1552.
6. John T. NHL in children 20 years population -based epidemiological study in western Sweden. J-pediatric hematology 1999mar-apr 21:87-8.
7. Rena Buckstei, Burkitts lymphoma treatment policy, uklg-lyog study .1990:11-22.
8. John H. Sinard. Out lines in pathology, London, W.B. Saunders company, 1996:page 93-99.
9. Stanley L. Robbins- Robbins Basic pathology. 7th ed Saunders company 2003:page 419-429.
10. Seymour Swchartiz. Principles of surgery, McGraw-hill seven edition 1999: 1244.
11. James A. O Nill Jr. pediatric surgery 5th ed, Mosby 2000 461-470.
12. John T. sandlund ching. Houpu, NHL of childhood, Hopus Bangkok-Thailand October 1999 :24-28.
13. Mitchell's Cairo. Sherrie Perkins NHL in children. Ann.surgery, 1990: 196:138-145.
14. G.M. Mead, *et al.* An international evaluation of CODOX-M and CODOX -M alternating with IVAC in adult Burkitts lymphoma, result of united kingdom lymphoma group LYO 6 study. Annals oncology. 2002:13:1264-1274.
15. Arturo Molina, Cancer management a multidisciplinary approach fifth edition. 2001:5:1-27.

**Table -1-Initial surgical procedure and survival in abdominal NHL**

	Presentation and type of surgery	No . of patients	No . of patients survived	Survived rate %
1	Abdominal mass	28	16	57%
	Debulking	18	12	66%
	Biopsy or FNA cytology	10	4	40%
2	Acute abdomen	6	5	80%
	Intussusception	3	3	100%
	Appendicitis	2	2	100%
	Intestinal obstruction	1	0	0%

# Management of abdominal Non-Hodgkin's lymphoma in children in mosel

### Age and sex

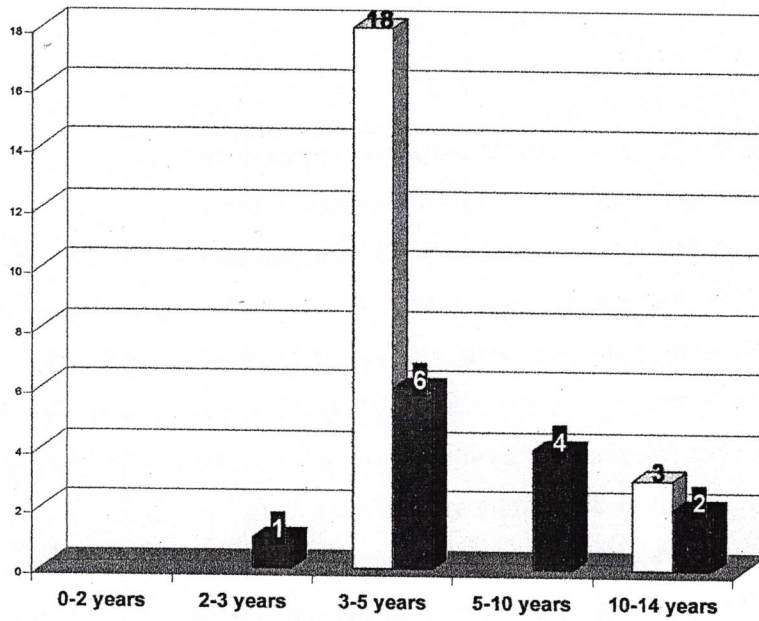


figure-1-age distribution between male and female

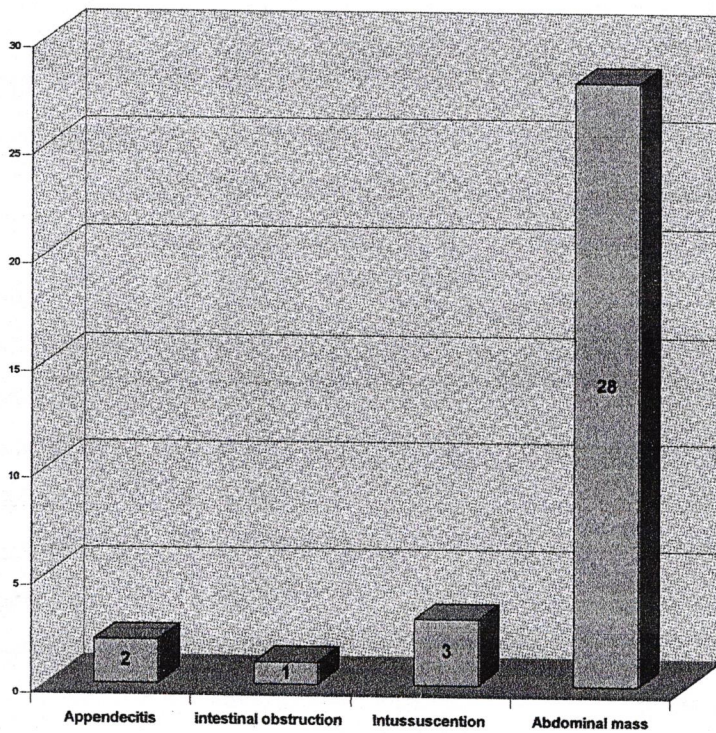


Figure -2-presintation of the patient