

Transcanalicular laser dacryocystorhinostomy

Abdulhameed A. Hassan. ,Khalid A.Fleah

Dept. of surgery, College of medicine, university of Kirkuk., Dept of surgery, college of medicine , university of Tikrit. Iraq

Abstract

The objective of this study are to describe the technique, evaluate the effectiveness of TCLDCR with diode laser in the treatment of epiphora in adult and to review the published results after TCLDCR. A prospective , interventional case series was designed in 28 patients presenting with epiphora due to NLD Obstruction .**Materials and Methods:** At private sector as a day case surgery in Kirkuk city the procedure was performed under general anesthesia. We achieved osteotomy by applying laser energy via an optic fiber, using a 980 nm diode laser with power of 10 Watts. At the last step bicanalicular silicone stent was inserted . Success of procedure was absence of epiphora (subjective), or patency of the lacrimal drainage system on irrigation (objective). **Results:** We performed 28 successive transcanalicular laser (TCL-DCR) with bicanalicular silicone tube intubation in 26 patients and monocanalicular silicone tube intubation in 2 cases. The average procedure time was 20 min. The silicone stents were removed three to six months after surgery. We observed absence of epiphora and a patent nasolacrimal duct on irrigation in 23 out of 28 treated eyes after six to thirty six months after operation. Five patients had epiphora despite an initial successful nasolacrimal duct intubation. This yields a success rate of 82%, with an average follow-up period of 12 months. **Conclusions:** The 980 nm EL-DCR with silicone tube intubation is a new contribution to the field of lacrimal surgery. It is a minimally invasive quick procedure yielding a high success rate.

Key words; laser DCR ,lacrimal surgery ,minimally invasive lacrimal surgery

Introduction

Dacryocystorhinostomy consists of creating a lacrimal drainage pathway to the nasal cavity to restore permanent drainage of the previously obstructed excreting system through an opening made at the level of lacrimal bone(1). Traditionally the treatment of nasolacrimal obstruction is external dacryocystorhinostomy frequently performed by ophthalmologists.

The history of lacrimal surgery dates back from Hammurabi(2,200B.C)(2,3). The first intranasal approach was described in 1889 by Killian, and endoscopic dacryocystorhinostomy was first performed by Caldwell in 1893, but was soon abandoned due to difficult visualization and numerous complications.(4) However, with the advent of new technology used in endoscopic sinus surgery, permitting better visualization, the endoscopic approach has been revived.(5) This approach permits direct visualization of the lateral nasal wall in the middle nasal meatus, where the osteotomy is performed.

The last step in the development of less traumatic DCR is the endocanalicular approach, first described in 1963 by Jack, a probe is inserted through the lower lacrimal punctum via the canaliculus into the lacrimal sac following the anatomical pathway of tear outflow.(6) Osteotomy is performed either by a mechanical drill or laser energy through an optic fiber, which is inserted within the probe.(7)

Lasers with several different wavelengths have been used to perform osteotomy as part of the DCR procedure, mostly as part of a transnasal approach.(8) The first laser described for clinical use in DCR procedure was the KTP laser in 1993 by Reifler.(7) The use of a diode laser for EL-DCR has been first reported by Eloyetal. in 2000, followed by Fernandez etal. in 2004.(9,10). The purpose of our prospective study was to analyze the success rate of TCLDCR with a 980 nm diode laser in a series of 28 successive procedures.

Materials and Methods

28 patients of chronic dacryocystitis without any nasal pathology were included in this study. (5) patients were male, while (23) were female. Right eye was involved in (15) cases while left eye was in (13) cases. Age varied from 20 years to 69 years.

Diode laser having 980 nm wavelength source (ECLAD, Biolitic Biomedical Technology, made in Germany), in repetitive pulse mode. The laser settings were: Power 10 W, pulse length 90 ms, pause between pulses 50 ms was used. Optical fiber which was used of 360 micron size thickness. Two 11mm long and 23 G size probe with attached silicone tube were used for intubation.

Procedure: The procedure was performed under general anesthesia in private sector as day case surgery at Kirkuk city. The nasal mucosa of the lateral nasal wall packed with gauze soaked with decongestant (epinephrine 1:1.000).

After proper draping, lower punctum was dilated with dilator and then lower canaliculus was also gently dilated using different size of lacrimal probes. Laser fiber optic cord was passed through tunnel of blunt tipped 21G and 9mm long spinal needle. It was then gently introduced through lower canaliculus into the sac until some resistance by bone was felt.

When the fiber probe reached close to the bone, laser shots were fired intermittently till a small opening was created as seen by an ENT surgeon so as to make sure the correct position of the opening in the superoanterior part of the attachment of middle part of turbinate. By gentle to and fro movements of the needle, fiber optic end could be seen as lighted end through the nasal mucosa. Laser energy was used only for couple of minutes to create an opening. The opening was gently enlarged by giving some more laser shots on the margin. It was also made sure that there was no bleeding. Syringing was done to make sure that the passage was patent.

The next step in the procedure consisted of intubation with a bicanalicular silicone stent in the first 26 cases and with two monocalicular tubes in the following 2 cases. Tamponade of the nasal cavity was performed in cases of bleeding from the mucosa. One probe with silicone tube was introduced through lower punctum and allowed to pass through the lacrimal passage till its ends were seen protruding in the nasal cavity. It was gently pulled out with artery forceps by an otolaryngologist. Similarly another probe

was fashioned through upper punctum, this would ease to loupes of tubings near medial canthus.

Both probes were cut and removed. Silicone tubes were tied 6 to 10 times and placed in the nasal cavity in such a way that they would not give discomfort to the patients. Moreover, their ends would not slip or accidentally pulled out by patients.

Postoperative treatment included Dexamethasone-Neomycin-Polymixin B (Maxitrol) eye drops and nasal drops for three weeks on the treated side. Patency of the nasolacrimal duct was determined as absence of tearing and/or successful irrigation of the lacrimal passages. They were followed up next day, after one week, one month, 3 months. After 3 to 6 months, silicone tubes were removed after cutting the "U" loupes band at medial canthus. Patients were advised to continue drops and were followed again after one month for check.

Results

We performed 28 successive TCLDCR procedures with bicanalicular intubation in 26 patients and monocalicular intubation in 2 cases between June 2010 and June 2013; 23 females and 5 males; (average age is 42 years, range 20-69). The average procedure time was 20 min (range 10-45 min), to produce a small size osteotomy show table (1) and fig (1).

We noticed swelling of the ipsilateral lower eyelid in six cases, and bruising in four cases. The swelling usually resolved

in a day or two, and bruising was visible for approximately a week. Also in one female patient had previous history of cataract surgery conjunctival burn has occurred, and upper lid burn in another case too. On nasal part of the surgery two patients were developed bleeding during surgery, however controlled with nasal tamponade, but after removal of stents we noticed synechiae in two cases only and released after that, and one female patient developed granuloma. Removal of the silicone stents done on average six months after surgery (range three to nine months), however in two patients the silicone stents were removed accidentally while rubbing the eye & cleaning the nose. The patients after silicone stent removal were re-examined, and the follow-up time range was (6-36 months). We observed absence of epiphora and a patent nasolacrimal duct on irrigation in 23 out of 28 treated eyes. The causes for re-obstruction were fibrosis of the site of osteotomy in four cases and development of granuloma in one case. This yielded a success rate of 82% show fig (2).

Discussion

When epiphora persists despite probing or intubation surgical intervention with either external or endoscopic endonasal DCR is usually the next preferred treatment modality. Endocanalicular laser DCR represents one of many recent attempts to improve lacrimal surgery (11). TCLDCR is a minimally invasive

surgical procedure. It takes advantage of accessing the operating field through anatomic pathways (the lacrimal canaliculus). This contributes greatly to minimizing trauma to surrounding tissue and avoiding unnecessary surgical skin scars. On the other hand, Toti's classic external approach with a 90-95% success rate remains the golden standard, compared to the 80-85% success rate of transnasal DCR procedures and 70-80% success rate of TCL-DCR. (12,13) show fig (3).

Of course there are certain disadvantages of this procedure: Some concern handling of the laser and the costs of it show table (2).

One of the main problems is adequate osteotomy size, as re-stenosis at the site of osteotomy is one of the leading causes of long-term failure in DCR. (14) An osteotomy of more than 10 mm in diameter can be routinely achieved by the classic approach, and a slightly smaller osteotomy of 7-9 mm is achieved with the transnasal approach. (12). An interesting computed tomography study by Yazici and Yazici showed that final nasal ostium size six months after surgery is in no correlation with osteotomy size at time of surgery and suturing of mucosal flaps, and measured from 3.1 to 3.8 mm in height. (15) Other factors play a role in the development of re-stenosis, as tissue trauma with subsequent inflammatory response and scarring and Natural Healing of the nasal mucosa across the opening. So, for better results one has to be judicious in applying

lasers that under constant guidance of assisting ENT surgeon. And to overcome, natural healing, silicone tubing can be a very good option as it can allow epithelialization around tubes so that after removal of tubings, the opening can remain patent. Even when tubing were not removed, patients were comfortable and had no watering which reveals that fluid would trickle down the lacrimal passage along the tube.

Passage remained patent even after removal of tubing. However long term follow up is recommended.

The patients from our study reported little or no pain postoperatively and were able to leave the same day after surgery, which is a great advantage over classical or Trans Nasal Endoscopic-DCR.

The amount of lid swelling and bruising was also significantly less compared to classical or TNE-DCR.

The success rate of our study (Transcanalicular diode laser-assisted DCR) is comparable with other highest successful results reported for any DCR procedure other than classical DCR shown in fig.3 and (table 2). (8,11,16,17,18), We explain this by minimal trauma to tissue, which results in minimal postoperative inflammation and scarring. Additionally, in cases of re-stenosis, the procedure can be easily repeated, as there is no scarring of the lacrimal pathways and change in anatomical relations.

Silicone intubation along with Laser DCR in 28 cases was easy intraoperatively and gave better patency

of lacrimal passage as compared to only Laser DCR in cases of chronic dacryocystitis.

Conclusions

Transcanalicular diode laser DCR is an effective procedure for treating primary NLDO in adults and compares favorably with success rates of external and endoscopic endonasal DCR. This procedure may provide a significant alternative to transcutaneous approach. A teamwork with an ophthalmic surgeon, and an ENT surgeon is expected to provide the optimal preoperative evaluation, surgical treatment and postoperative care. We advise all patients with gross anomalies in nasal anatomy to undergo rhinologic treatment first.

We need larger series and longer follow-up periods for better understanding of the Transcanalicular diode laser DCR technique and its results for treating primary NLDO

Laser DCR has many advantages over conventional methods when a patient is anti coagulated or has a coagulopathy. A relative indication for laser DCR is for revision surgery for a failed external DCR when there is often only a thin membrane blocking the rhinostomy.

References;

1. Rajat M. MS Endoscopic endonasal dacryocystorhinostomy; A review Available from <http://theidos.com/Dr-Rajat-Maheshwari-Article.aspx>. 2012
2. Buses H. Short and long-term results of dacryocystorhinostomy externa after

- Kaleff-Hollwich invest ophthalmol.1977; 171:986-989Augenheik.
- 3.Busse H. , Hollwich F .Diseases of the lacrimal drainage system and its treatment of the library ophthalmologist1978; 74:2-6.
- 4.Mahmmod S., Sadiq A. A short history of lachrymal surgery.CME journal ophthalmol .2001;5:76-8.Available from <http://www.rila.co.uk> { last accessed on 2007 Dec.29}.
- 5.Kennedy DW. Functional endoscopic sinus surgery technique .Arch Otolaryngol .1985;111:643-9.
- 6.Jack MK . Dacryocystorhinostomy: Description of A transcanal method. Am J ophthalmol.1963;56:974-7.
- 7.Reifler DM. Results of KTP laser-assisted dacryocystorhinostomy Ophthalmoplast. Reconst. Surg.1993;9:231-6.
- 8.Brigita Drnovsek-Olup.,Matej Beltram. Transcanalicular diode laser dacryocystorhinostomy.2010;volume 58 issue3page:213-217.
- 9.Eloy P., Trussart C., Jouzdani E., Collet S., Rombaux P., Bertrand B. Transcanalicular diode laser assisted dacryocystorhinostomy. ActaOtorhinolaryngolBelg .2000;54:157-63.
- 10.Alpon Fernanadez FJ., Alapon Fernandez MA .,Martinez Fernandez A., Cardenas Lara M .Transcanalicular dacryocystorhinostomy technique using diode laser in Spanish Arch SocEspOftalmol. 2004;74:395-401.
- 11.Hong JE., Hatton MP., Leib ML., Fay AM. Endocanalicular laserdacryocystorhinostomy. Analysis of 118 consecutive surgeries. Ophthalmology.2005; 112:1629-1633
- 12.Olver J. Colour Atlas of Lacrimal Surgery. Oxford: Butterworth-Heinemann. 2002; p. 98-9.
13. Mandeville JT., Woog JJ. Obstruction of the lacrimal drainage system. Curr OpinOphthalmol. 2002;13:303-9.
- 14.Linberg JV., Anderson RL., Bumsted RM., Barreras R. Study of intranasal ostium external dacryocystorhinostomy. ArchOphthalmol. 1982;100:1758-62.
- 15.Yazici B., Yazici Z. Final nasolacrimal ostium after external dacryocystorhinostomy. Arch Ophthalmol. 2003;121:76-80.
- 16.Elham Q., Yaser F. Transcanaliculardacryocystorhinostomy with diode laser .American society of ophthalmic plastic and reconstructive surgery.2007 available from([ebilbe teacher.com](http://ebilbe.teacher.com)).
- 17.H.-W.Meyer Rusenberg ,PP. Vujanceric, K.-H.Emmerich. Current status of dacryocystorhinostomy.Springer-verlag. 2009;p:13-15.
- 18.PlatoJM.,KelleP.,LimonS.,Quenos.Ho lmium-YAGand neodymium;YAGlaserassistedTranscanal iculardacryocystorhinostomy.Results of 317 first procedure(in French)JFr Ophth.2001;24(3).253-264.

Table-1: Total No. of Patients (28)

Sex		Eyes		Age (years)
Male	Female	Rt. Eye	Lt. Eye	
5	23	15	13	20 to 69

Table (2) Comparison with other studies

Authors	success rates
Pearlman	85%
Philips B,	46%
Plato JM ,Keller P,Limon	70%
HofmanT,Lackner A.	83%
Alanon	90%
Elham,Yasser al-kaftany	88%
BrigitaD,Matej B.2010	83.30%
Abdulhameed,Khalid	82%

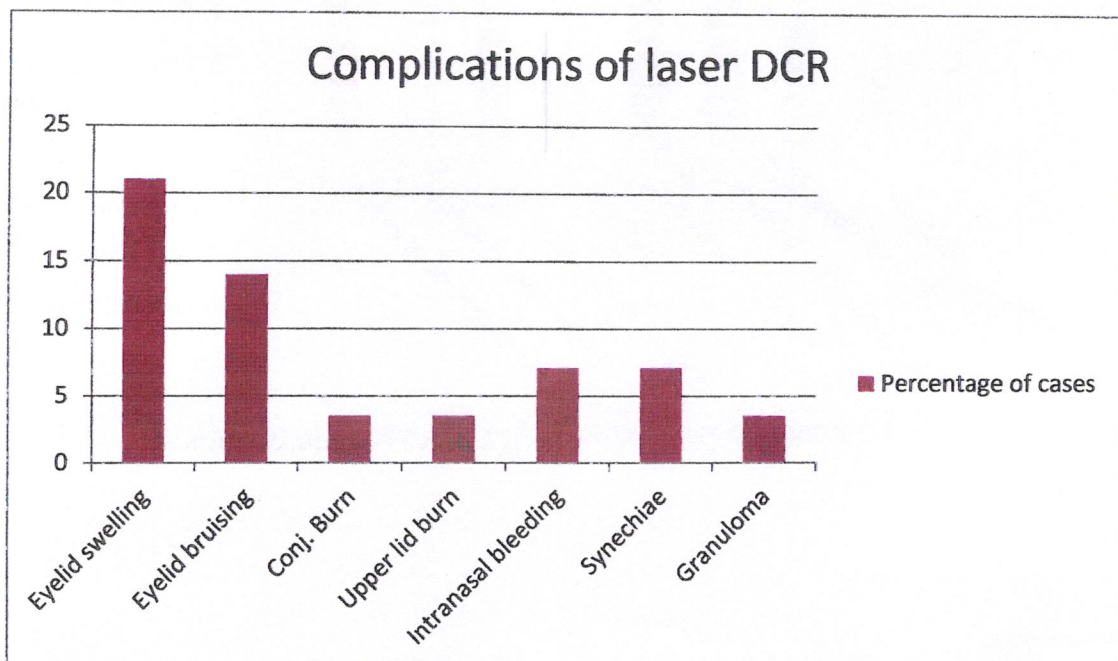


Fig.(1) Complications of Transcanalicular laser DCR

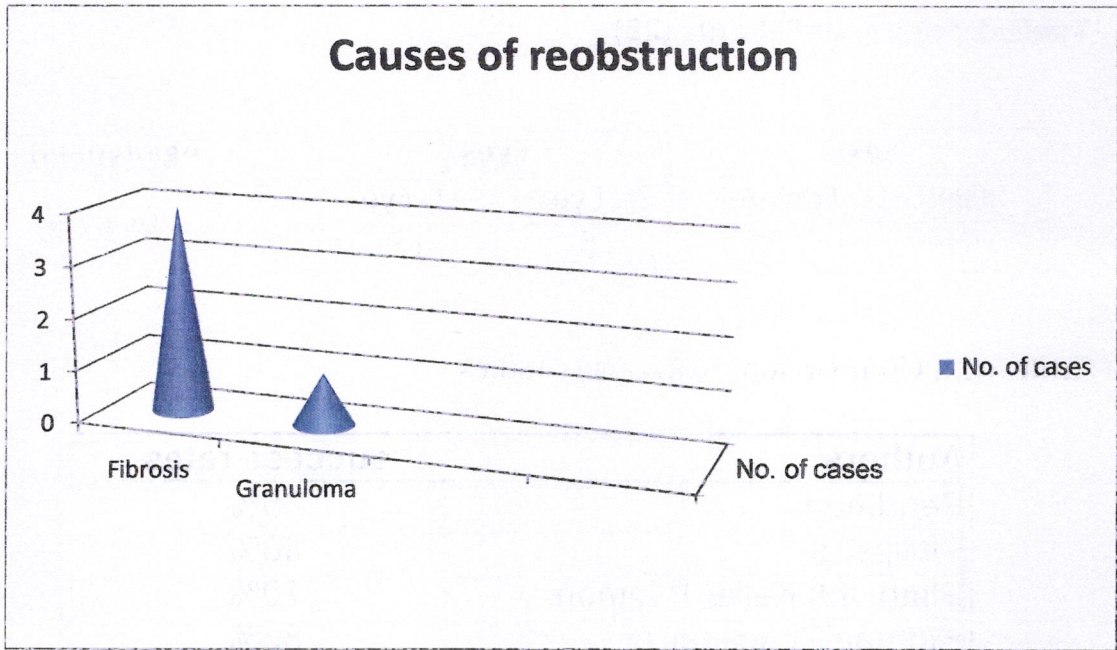


Fig. (2) Causes of reobstruction

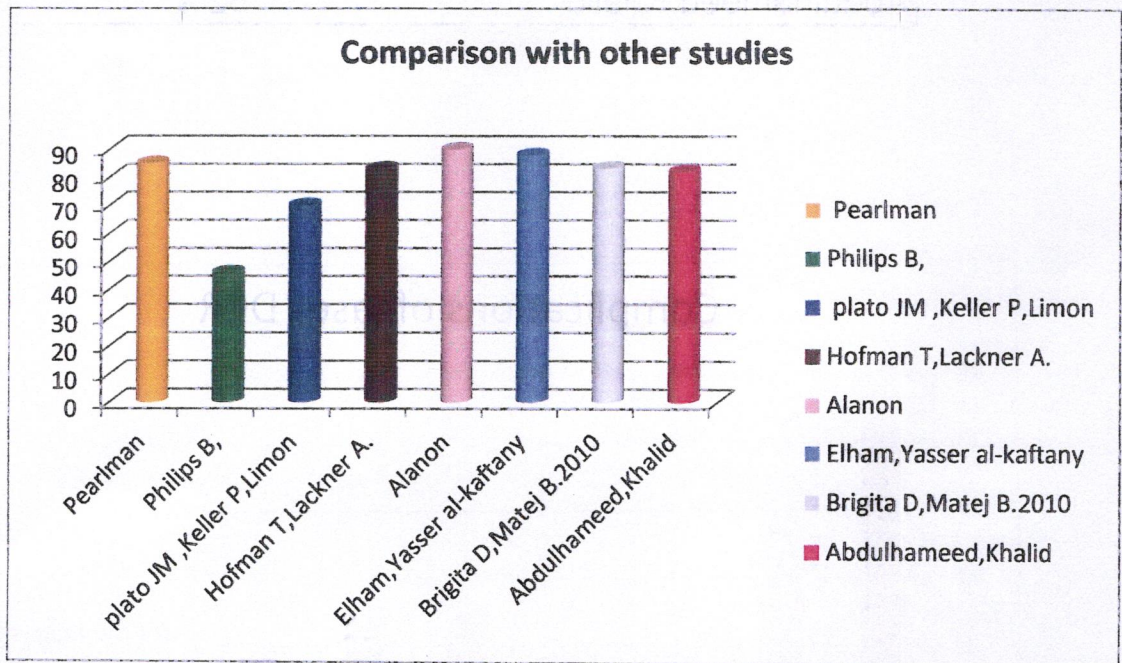


Fig. (3) Comparison with other laser DCR procedure(studies)