

## CT and MRI with operative findings; a comparative study of otorhinolaryngology

*Ibrahim A.S. Al-Sabawee, M.B.Ch.B. F. I. C. M. S. E. N. T*

*Department of Otolaryngology, Assalam Teaching Hospital, Mosul, Iraq.*

### Abstract

**Aim:** To confirm the accuracy of updated imaging investigations in disorders of otorhinolaryngology and to support the commitment of the surgeon toward the proper surgical procedures of these disorders.

**Study design:** A prospective and comparative study of updated imaging (CT scan and MRI) of otorhinolaryngological disorders in 72 patients with transversal cohort (2012-2014).

**Materials and methods:** Seventy-two patients attended Assalam Teaching Hospital, Otorhinolaryngology department Mosul, Iraq, from January 2009 to November 2009. The patients were subjected to CT scan and/or MR imaging, included 32 patients with sinonasal disorders, 30 patients with laryngopharyngeal disorders, and 10 patients with otological disorders. The age distribution of the patients range from 2 months – 75 years, with a mean age of 38 years, with sex distribution of 52 males and 20 females. The objectives of this study are to evaluate the diagnostic value of CT scan and MRI in otorhinolaryngological disorders and to compare the result with the operative findings.

**Result:** For sinonasal tumors; in bone distraction, the accuracy of CT scan was 100 % and for MRI 66%. In intracranial extension the accuracy of CT scan was 50% and for MRI 87%. In tumor staging by CT scan, the accuracy was 75% and for MRI 87%. For bony hard lesion, the accuracy of CT scan 100% , were in 2 patients, one of them was un irraptured tooth, and the other was bilateral choanal atresia. For the larynx; Paraglottic space involvement, the accuracy of CT scan was 88% and for MRI 86%. Extra laryngeal spread the accuracy of CT scan was 75% and for MRI 71%. Cartilaginous invasion the accuracy of CT scan was 81% and for MRI 79%. For the ear; Bony erosion the accuracy of CT scan was 80% and for MRI 66%. Space occupying lesion (brain abscess) the accuracy of CT scan was 100% and for MRI 100%. Chronic mastoiditis (cholesteatoma) the accuracy of CT scan was 80% and for MRI 66%.we have concluded that, the updated imaging becomes a well-defined signs and has many fundamentals in relation to otorhinolaryngological disorders.

**Conclusion:** Updated imaging (CT and MRI) becomes a well-defined signs and has many fundamentals in relation to otorhinolaryngological disorders. Coronal and axial CT views are the most useful views in the nose and paranasal sinuses, also CT was superior to MRI in detecting neoplastic bone disorders especially with early bone erosion, While MRI is important to differentiate between retained secretions and neoplastic lesions (benign and malignant).

## **Introduction**

The role of CT and MRI become increasingly important for the otorhinolaryngological disorders, giving the surgeon the ability to know the nature, extent, state of the neighboring organs and the feeding vessels, CT and MRI in the last few years, made the most important contribution of radiology to otorhinolaryngology. CT represented a great advance in soft tissue imaging because of its greatly improved density resolution. Recently, CT has an improved spatial resolution for structures of high inherent contrast, such as bones like temporal bone and paranasal sinuses. The properties measured by MRI vary widely between different soft tissue types. The main advantage of MRI over X-ray techniques is its superior soft tissue differentiation. A further advantage is the accessibility of any desired image plane without physical adjustment of either the imaging system or the patient. It is important to know the plan how to manage those patients with otorhinolaryngological disorders, so that the advancement in CT and MRI facilitate the job of the surgeon to treat the disease in otorhinolaryngology 1.

## **Materials and methods**

This is a prospective and comparative study that had done from January 2009 to November 2009 at Assalam Teaching Hospital, Otorhinolaryngology department in Mosul, Iraq. The study included 72 patients. Thirty-two patients complained of nasal problems, 30 patients of throat problems and 10 patients of ear problems. Seven-teen patients with neoplastic lesions of the nose and paranasal sinuses, 30 patients for laryngeal carcinoma. In addition, 2 patients of squamous cell carcinoma of the external auditory meatus. For inflammatory disorders 13 patients with nasal problems,

no patients for the larynx, and 8 patients with chronic mastoiditis. Miscellaneous cases are 2 patients for the nose and paranasal sinuses, one of them unruptured tooth and the other was bilateral choanal atresia. From those 32 patients who complained of nasal problem, CT done for 18 patients and MRI for 15. Total maxillectomy was done for 5 of them, endoscopic sinus surgery for 11, Laffort II for 4, septoplasty for 2, Caldwell Luc for 1 patient, Laffort I for 2 patients, opening of the posterior choanae for 1, external frontoethmoidectomy for 2, medial maxillectomy for 2 and excisional biopsy for 2 patients. For the throat disordered patients, CT was done for 16 patients and MRI for 14. The operations which were done for them are total laryngectomy for 30. For the ear complaint patients, CT scan done for 10 of them and MRI for 6. Modified radical mastoidectomy done for 6, right parotid gland excision and right modified radical mastoidectomy for 2, cortical mastoidectomy for 2. CT of nose and paranasal sinuses done for 18 patients and the most frequently section used was coronal then axial with 2-3 mm thickness slices, and most of them with contrast enhancement. MRI of the nose and paranasal sinuses done for 15 patients, axial view most frequently used with increased intensity of T2 after contrast injection. CT of ear done for 10 patients, the axial view most frequently used was 3-8 mm thickness slice, and most of them without contrast. MRI done for 6 patients of the ear disorders with axial view and most of the pathologies was isointense in T1 weighted image with increase enhancement after contrast injection. CT of the throat done for 16 patients, axial and coronal view used with 3-8 mm thickness slices, contrast enhancement observed in all of them. MRI of the throat done for 14 patients and T1 weighted image used,

## CT and MRI with operative findings; a comparative study of otorhinolaryngology

showing isointensity and T2 weighted image showing hyperintensity. The presenting symptoms and durations for the nose, which may include; nasal obstruction, discharge, bleeding, pain, postnasal drip and face and eye abnormality. For the ear, may include; pain, discharge, hearing loss and headache. For the throat, including; hoarseness of voice, stridor, dysphagia and lymph node enlargement. Past history of similar condition and other diseases. Surgical history and previous operation, family history of the same illness or other ENT problems, thorough ENT examination, general examinations, cranial nerves examinations.

Investigations were routinely done to confirm the fitness for general anesthesia according to the age and general state of health of the patient, all patients sent for either CT or MRI or both. Radiological findings were categorized into the followings; CT and MRI of the nose and paranasal sinuses. The Most complete examination of the paranasal sinuses and nasal fossae is obtained by a combination of axial and coronal studies of 5mm thickness slices<sup>2</sup>. The findings are soft tissue mass, bony erosions, intra cranial or extra cranial extension and intranasal or extra sinus extension. For CT and MRI in the ear; in order to reduce the cataract due to diagnostic radiation; axial plane angled 30 above the canthomeatal line of 0.5 mm thickness slices, the majority of patients need CT or MRI to see the evidence of complication such as intracranial extension, brain abscess, labyrinthine fistula or feature of mastoiditis<sup>2</sup>, soft tissue mass, bony erosion, sclerotic mastoid, intra cranial extension and space occupying lesion (brain abscess).

For CT and MRI in the throat; CT and MRI have improved the ability to demonstrate the local spread of laryngeal cancer defining several pattern of invasion

to anterior commissure, paraglottic space, extra laryngeal extension and cartilage invasion<sup>2</sup>. Localized swelling or mass location, whether, glottic, supraglottic, subglottic and cartilaginous invasion. The operative findings; for the nose and paranasal sinuses; hard mass with well-defined capsule, soft tissue mass, mucosal thickening with hypertrophied inferior turbinate, mucocele, mucous fluid cyst, unerrupted tooth and bony choanal atresia. For the ear; polyp, cholesteatoma, bone erosion, granulation tissue and brain abscess. For the throat; soft tissue mass glottic, supraglottic, subglottic, obliteration of the laryngeal cavity, extra laryngeal extension and cartilaginous invasion.

## Results

Shown fig 1,2,3

## Discussion

The patients' sex distribution in this study was 52 male and 20 female and the age range was 2 months – 75 years with a mean of 38 years. Of these, 32 patients for nasal problems, 30 for laryngeal problem, and 10 for aural problems. The total number of CT scan performed 44(56.6%) and for MRI 35(44.4%). For sinonasal tumor are often discovered when they are quite large because these lesions are a symptomatic or cause non – specific symptoms when they are small<sup>3</sup>. Rankin et al<sup>4</sup> In his study found the accuracy of CT in tumor staging 80% , while Maha et al<sup>5</sup> found in her study accuracy of 73%. These agree with this study, which is 75% accuracy. For MRI accuracy the result of Rankin et al<sup>4</sup> and Maha et al<sup>5</sup> are 94% and 93% respectively. These agree with this study, which is 87%, so MRI plays a critical role in evaluation of

sinonasal neoplasm<sup>6</sup>. For bone destruction the accuracy of CT and MRI in Maha et al<sup>5</sup> study were 92%, 66% respectively so bone details is more precisely imaged by CT scan than MRI (7,8,9). This agrees with this result, which is 100% and 66% respectively. Therefore, the combination of CT scan to evaluate the bony architecture with MRI to differentiate tissue density and predict with near perfect accuracy the difference between tumor bulk and retained secretions in the sinuses has introduced a new era in planning of sinus neoplasm management<sup>10</sup>, the sinonasal neoplasm can extend intracranial across the anterior skull base<sup>11</sup>. For intracranial extension, accuracy of CT and MRI. Mah et al<sup>5</sup> found accuracy of 50% and 100% respectively which is similar to this study of 50% and 87% respectively. For the hard bony lesion who have 2 patients one unerrupted tooth and the other was bilateral choanal atresia, the accuracy of CT was 100% in detecting them. For the larynx; the larynx is a difficult organ for radiological imaging because respiration and swallowing can cause several artifacts and imaging distortion<sup>12</sup>. M. Becker<sup>13</sup> in his study found a sensitivity of 100% for CT for detection of a tumor involving and paraglottic space and a specificity of 93%, and Bruning et al<sup>14</sup> with bloom et al<sup>15</sup> and Abdul Monem et al<sup>16</sup> where they found a specificity .of CT 93%. The paraglottic space lies between the mucosa and the laryngeal framework and is paired and symmetrical. In the supraglottic region, it surrounds the laryngeal ventricle and mainly contains fat, whereas at the glottic level the thyroarytenoid muscle, which forms the bulk and shape of the vocal cord occupies most of the volume of the paraglottic space. Within the paraglottic space, tumors may easily spread in a cephalad or caudad direction to areas that are remote from the site of the primary mucosal lesion. Therefore, these

tumors are often diagnosed in an advanced stage. The primary sign of tumor spread to the paraglottic space on both CT and MR images is replacement of fatty tissue by tumor tissue. Recent radiologic-pathologic correlation studies show that neoplastic invasion of the paraglottic space may be equally well detected with both techniques<sup>13, 17</sup> These agree with this result which is found to be a sensitivity of 90 % and specificity of 83% after operative exploration and histopathological examination. For MRI study by M. Becker et al<sup>13</sup> he found a sensitivity of 100% and a specificity of 97% for detection of tumor invasion to the paraglottic space Abdul Monem et al<sup>16</sup> and Bruning et al<sup>7</sup> found a specificity of 97% and a sensitivity of 100%, while Bloom et al<sup>15</sup> found MRI specificity of 84%-90%. These agree with this result, which are found to be a sensitivity of 88% and specificity 83% after operative exploration and histopathological examination. For CT study by M. Becker et al<sup>13</sup> for extra laryngeal invasion, he found a sensitivity and specificity of 44%, 95% respectively (very low sensitivity due to very late detection in the disease process). These agree with this result for sensitivity and specificity of 50% and 90% respectively. For cartilage invasion, M. Backer et al<sup>13</sup> found a sensitivity and specificity for CT 91%, 68% respectively. Abdul Monem et al<sup>16</sup> and Castelijns et al<sup>18</sup> and Geovanni et al<sup>19</sup> found a cartilaginous invasion by CT of a sensitivity of 91% and a specificity of 68%. These agree with this result, 80% and 83% respectively. The specificity very low because it's very difficult and impractical to confirm cartilage by means of biopsy .<sup>13</sup>

The MRI in cartilaginous invasion, M. Becker et al<sup>13</sup> found a sensitivity and specificity of 90 %, 80% respectively .Abdul Monem et al<sup>16</sup> and Castelijns et al<sup>18</sup> and

### CT and MRI with operative findings; a comparative study of otorhinolaryngology

Geovanni et al<sup>19</sup> found MRI a sensitivity and specificity of 90 % and 80 % respectively. These agree with this result, which are found to be a sensitivity and specificity of 78%, 80% respectively. M. Becker et al<sup>13</sup> the accuracy of CT and MRI for invasion and staging the laryngeal tumor are 80%, 85% respectively. These agree with this result, which are 81%, 79% respectively.

For the ear; Veillon et al<sup>2</sup> found the accuracy of CT 85%. These agree with this result, which are 80% for the accuracy and 88% for the sensitivity. Veillon et al<sup>2</sup> found the accuracy of MRI in bony erosion 60% and sensitivity 72%. This is corresponding with this result, which are 66% for the accuracy and 75% for sensitivity. Veillon et al<sup>2</sup> found in his study for space occupying lesion (brain abscess) the accuracy of CT is 100%. This is similar with this study, which is 100% accuracy. Veillon et al<sup>2</sup> found the accuracy of MRI in space occupying lesion (brain abscess), 100%. These agree with this result which is of accuracy 100 which is found in two patients in this study. Veillon et al<sup>2</sup> found the accuracy of CT and MRI 85%, 70% respectively for detection of cholesteatoma. These agree with this result, which are 80%, 66% respectively. The results obtained showing a slight CT and MRI limitation, which is may be due to; variation of radiologist's reading, variations of the type of machine used and the time between CT or MRI examination and surgical exploration.

### Conclusions

CT scan and MRI when indicated can be done for any patient, and the age of the patient is not a contraindication for this investigation.

Male patients more than female in general. It is obvious that the male patients in laryngeal disorder more than the female patients.

Coronal and axial views are the most useful views in the nose and paranasal sinuses. CT was superior to MRI in detecting neoplastic bone involvement especially with early bone erosion. The staging accuracy of carcinoma of the larynx by endoscopy increased significantly when combined with either CT or MRI (80%, 85%) respectively. The use of MRI is very important to differentiate between retained secretion and neoplastic lesion. MRI possesses many advantages than other imaging modalities by its excellent tissue contrast. CT is mandatory for each patient with nasal problem if the conventional investigations fail to determine the disease. MRI is very important in detection of intracranial extension of any lesion in the nose, paranasal sinuses and ear. MRI is mandatory for T-staging of laryngeal cancer. Criteria for pathological MRI findings in the paranasal sinuses are desirable and might improve the basis for a decision on the correct medical or surgical treatment. MRI imaging findings of tumor volume and cartilage invasion for laryngeal carcinoma allows better patients selection for either radiotherapy or surgery.

### References

1. Scott-Brown's Otolaryngology 6th edition, Reed Educational and Professional Publishing Ltd 1997; Vol.1; Chapt. 17; Imaging and Radiography 1 – 10.
2. Veillon ,S.Riehm ; Imaging of The Temporal Bone and Face (Tumors and Pseudo Tumors ) Radiographic – Pathologic Correlations , European Radiology , 10 (Supl. 2) , S 69 –S 75 , 2000.
3. Cumming's otolaryngology Head and Neck Surgery 3rd edition, Mosby 1998; Vol.2; Chapt. 47; Neoplasm of Nasal Cavity 883-889.

CT and MRI with operative findings; a comparative study of otorhinolaryngology

4. Rankin S.: In Imaging in Oncology, Janet E.F. Husband and Rodney, Reznek ed. Jeromy M. Salter; publisher Santiago 1988, 415-428.
5. MAHA HELAL et al; malignant paranasal sinus neoplasm CT and MRI Characteristic ; The Egypt Journal of Radiology and Nuclear Medicine Vol. 31, No3 (sept.)2000:1005-1022 .
6. AHMED ABDEL KHALEK ABDEL RAZEK , et al ; MRI of Sino -nasal Neoplasm , The Egyptian Journal of Radiology and Nuclear Medicine Vol.31 , No3 (sept.) 2000; 957-965 .
7. MEDLINE 2000/01 -2000/10 The Prevalence and Significance of Incidental Paranasal Sinus Abnormalities on MRI, Tarp-B, Rhinology 2000 (March) 38(1):33-8.
8. Sievers -K.W., Paranasal Sinuses and Nasopharynx CT and MRI - Radiology Associates, Dortmund, European journals of Radiology 2000 (March ) 33 (3) 185 -202.
9. Dessi (Imaging of The Adult Sinusitis: Indications for Using Conventional Technique, CT and MRI) Rev-otorhinolaryngology-Bord .1999; 120 (3):173-6.
10. Lloyd (Optimal Imaging for Sino-nasal Malignancy). J. otolaryngology, 2000 July; 114(7):557-62.
11. Savy (Optimum Imaging for Inverted Papilloma), J. Laryngol - otol, 2000 Nov.; 114(11):891-3.
12. KORMAZ, H.CEREZCI, N.G; AKMANSU, H; DURSUN, E: A Comparison of Spiral and conventional Computerized Tomography Methods in Diagnosis Various Laryngeal Lesions. Eur Arch Otorhinolaryngol .255(3), 149-54, 1988.
13. M.Becker ,A -M. Kurt , Department of Pathology , University Hospital of Genova , Switzerland ; Infrahyoid Neck :CT and MRI-Imaging Versus Histopathology ; Radiologic - pathologic Correlatrions ; Eur . Radiol.10 (Suppl.2), S35-S68 (2000).
14. Bruning, institute of Klinische Radiologie, radiology 1999 Nov. 39 (11) 939 -42.
15. MEDLINE 1999/01-1999/10, Bloom -C; department of Radiology, University of Montreal, Canada.
16. ABDEL MONEM NOOMAN A. DARWIESH et al ; Helical CT in The Diagnosis of Laryngeal Carcinoma ; The Egypt journal of Radiology and Nuclear Medicine Vol. 31.No. 3 (sept. ) 2000 : 967-973 .
17. Xiao, Department of Otolaryngology. Changheng Hospital Shanghai 2000-03, 1998 October 12(10) 439-41., China.
18. MEDLINE (R) 1999 /01 -1999/10, Castelijns J.A Department of Radiology; Academic Hospital, Amsterdam. The Netherlands.
19. MEDLINE ® 2000/01-2000/10 (X-ray Imaging in Assessing the extension of Laryngeal Cancer) Giovanni. Rev-otorhinolaryngology -Bord 1999;120(3):155-9

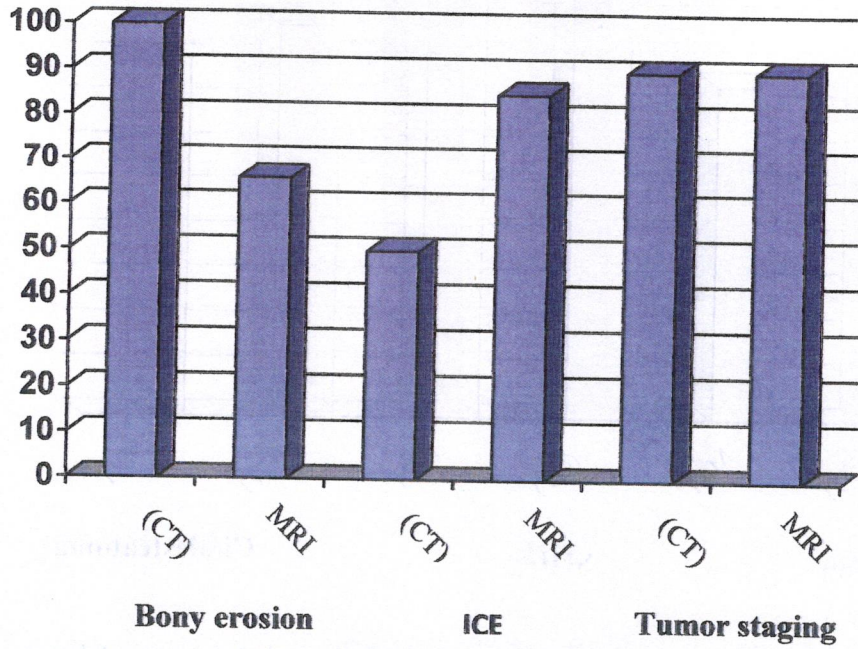


Fig (1): Bar chart for the sensitivity of CT and MRI in detection of bony erosion, intracranial extension, tumor staging in (31patients) for sinonasal tumors.

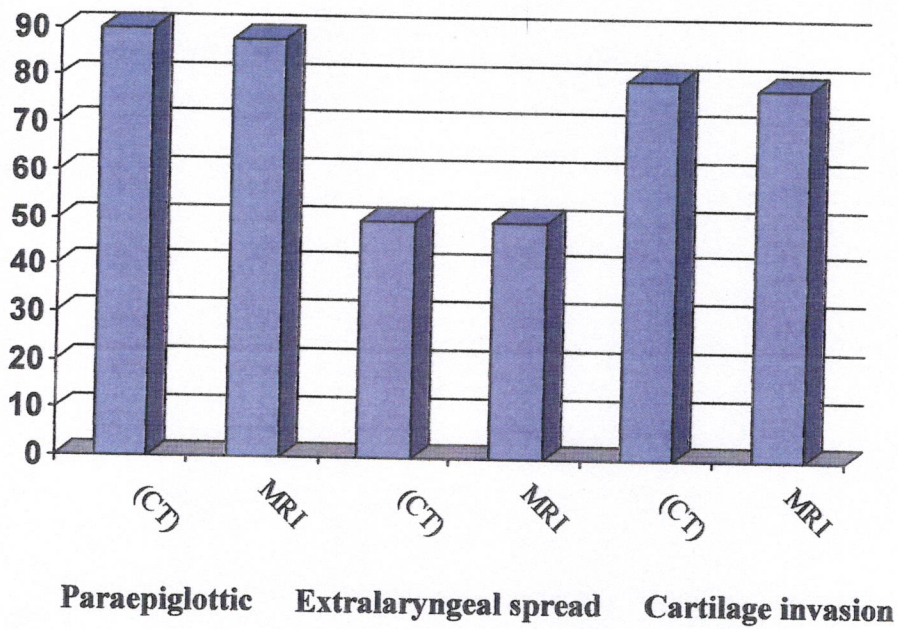


Fig (2): Bar chart for the sensitivity of CT & MRI in detection of para-epiglottic spread, extra-laryngeal spread, and cartilage invasion in laryngeal tumors (no = 30 patients).

CT and MRI with operative findings; a comparative study of otorhinolaryngology

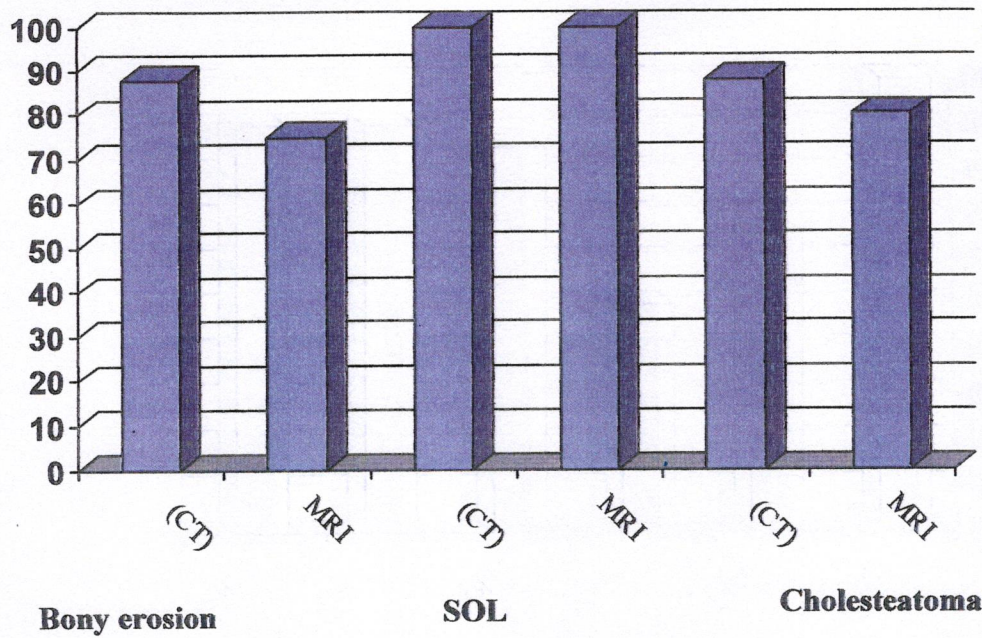


Fig (3): Bar chart for the sensitivity of CT and MRI in detection of bony erosion, space occupying lesion (brain abscess), and cholesteatoma in aural disorders in 16 patients.