

## Scalp traction folliculitis:Unreported entity in Iraqi female children

Osama M. AL-Juboori. MD, DDV, F.I.C.M.S.

Department of Dermatology & Veneriology, College of Medicine, Tikrit University. Salah - AL-Deen-Iraq. 2012.

### Abstract

**Background.** Folliculitis is inflammation of hair follicle caused by infection, chemical irritation or physical injury. Case series of scalp folliculitis in Iraqi female children (unreported previously) were identified; all patients had a history of mechanical traction. **Objectives.** To evaluate and characterize a new entity of scalp "Traction Folliculitis" apart from well known Traction Alopecia. **Patients and Methods.** A series of 45 patients with clinically diagnosed scalp folliculitis were observed to have "Traction Folliculitis" during the period from October 2008 and October 2011 in private practice using an observational study. History was obtained about age, residence, gender, previous similar lesions, type of hair style, coloring agents and associated signs and symptoms. **Results.** A total of 45 patients with clinically diagnosed scalp folliculitis were observed to have "Traction Folliculitis" of scalp, consisting of fine scalp scales, perifollicular erythema and pustules, associated with prominent hair casts. The presenting symptoms were pain (especially during cleaning and combing the hair), itching. There were lymphadenopathy in 7 patients (15.6%). No other similar skin lesions in nearby area in the neck or face, no nits of pediculosis capitis, no fragile crustation of impetigo. The disease from the first impression looks as if scalp pediculosis (pediculosis capitis), but there are no nits. Surprisingly the patients were all females with an age group between (1.5-11 year) ( $4.82 \pm 2.42$ ). The color of hair was brown in 38 patients (84.5%), black in 6 patients (13.3%) and only one blond girl (2.2%). Types of hair styles were ponytails (horsetail) with hair-cutters in 28 patients (62.2%), 2 lateral braids in 16 patients (35.6%) and one patient (2.2%) with 5 posterior braids. All patients were giving history of sustained severe hair traction. No curly hair, no black patients were observed. One patient (2.2%) mentioned using hair dye (Henna dye) as a coloring agent. This issue was solved and managed by changing the hairstyle, undo the traction, using mild antiseptic soaps and non irritant shampoos, some required systemic antibiotics for one week. It is unreported before as a separate entity as Traction Folliculitis and could easily passed or categorized as pediculosis capitis due to the similarity of hair casts with nits. The age group was mainly preschool age 33 patients (73.3%) and few primary school ages 12 patients (26.7%).

### Introduction

Folliculitis is inflammation of the hair follicle caused by infection, chemical irritation or physical injury. Inflammation may be superficial or deep in the hair follicle. Folliculitis is very common and is seen as a component of a variety of inflammatory skin diseases (<sup>1</sup>). Superficial folliculitis could be caused by Staph. aureus and physical or chemical irritation. The deeper forms of staph. folliculitis are furuncles and carbuncles.

Other microbial causes of folliculitis include Pseudomonas aeruginosa, Gram-negative folliculitis, Pityrosporum yeast and Dermatophytes. Patient with human immune deficiency virus disease may have itchy folliculitis of uncertain cause (<sup>2</sup>). Scalp folliculitis was observed as a component of traction alopecia with hair casts (<sup>2</sup>). Unexpectedly similar observations of unreported entity of traction folliculitis published in January 2007(3), and in Chili of 6 cases caused by hair



pulling, all the patients were women aged between 12 - 26 years (4).

## Patients & methods

A series of 45 patients with clinically diagnosed scalp folliculitis were observed to have "Traction Folliculitis" during the period from October 2008 and October 2011 in private practice using an observational study. History was obtained about age, residence, gender, previous similar lesions, type of hair style, coloring agents and associated signs and symptoms. Traction folliculitis was consisting of fine scales, perifollicular erythema, pustules, associated with hair casts. The presenting symptoms were; pain especially during combing, itching and there were no lymphadenopathy except in 7 patients. No other similar skin lesions in nearby areas in the neck or face. No nits of pediculosis capitis, no fragile crustations of impetigo. All the patients were females with an age group between (1.5-11 years). The color of hair was brown in 38 patients (84.5%), black in 6 patients (13.3%) and only one blond girl (2.2%). Types of hair styles were ponytails (horsetail) with hair-cutters in 28 patients (62.2%), 2 lateral braids in 16 patients (35.6%) and one patient (2.2%) with 5 posterior braids. All patients were giving history of sustained severe hair traction. No curly hair, no black patients were observed. One patient (2.2%) mentioned using hair dye (Henna dye) as a coloring agent. This issue was solved and managed by changing the hairstyle, undo the traction, using mild antiseptic soaps and non irritant shampoos, some required systemic antibiotics for one week. It is unreported before as a separate entity as Traction Folliculitis and could easily passed or categorized as pediculosis capitis due to the similarity of hair casts with nits. The age group was mainly preschool age 33 patients (73.3%) and few primary school ages 12 patients (26.7%).

## Results

All these 45 patients were females with scalp traction folliculitis mainly in preschool girls 33 patient (73.3%) and few in primary school age 12 patients (26.7%) with brown hair in 38 patients (84.5%), black hair in 6 patients

(13.3%) and only one blond girl (2.2%). Majority of hair-style was ponytail in 28 patients (26.2%), 2 lateral braids in 16 patients (35.6%) and one with 5 posterior braids (2.2%). The majority were from urban area 27 patients (60%) and the others from rural area 18 patients (40%). Duration of folliculitis was between 5-30 days Also 13 patients (28.9%) mentioned similar previous history of folliculitis. All the patients had hair casts, folliculitis, and scalp scales. No one had pediculosis nits. Minority of 7 patients (15.6%) had lymphadenopathy (occipital, preauricular). Mild hair loss was observed in 5 patients (11.1%) and the other 40 patients (88.9%) with no hair loss. Site of folliculitis was in maximal traction area in 26 patients (57.8%) and only in occipito-frontal area in 13 patients (28.9%) and in hair line in 6 patients (13.3%). The presenting symptoms were pain (88.9%) and itching in (17.8%) of cases. No history of fever observed or mentioned. Seven (15.6%) cases only were agreed to do scalp swab for bacterial culture that revealed *Staph. aureus* bacteria.

## Discussion

The severe sustained hair traction caused by excessive hair pulling could be the main cause for this type of folliculitis that was not reported before in such age group (preschool and primary school age groups). No history of using hot combs nor hair creams or gels. The observed bacterial infections in few cases could be secondary to scratching with unclean hand. The folliculitis were in female children, could be explained due to the long hair fashion in Iraqi girls and using hair pulling style like ponytail, or lateral braids. The mechanical traction of hair follicle induces mild inflammation of hair follicle (folliculitis) which induces pain. Correction of this trauma will solve the problem with mild shampoo or oral antibiotics. The underestimation of this entity and including traction folliculitis with traction alopecia in the textbooks of dermatology and not alone as a separate entity is worthy to be taken in consideration in the future. Also this type of folliculitis may be misdiagnosed as pediculosis capitis due to the similarity of hair casts with nits. This




is the first observational study of such traction folliculitis in female children in Iraq.

### Conclusion.

This entity could be explained due to sustained severe hair traction that induces mechanical irritation and then scalp folliculitis, that could be sterile or secondarily infected by itching with infected finger nails. The hair could be entirely corrected with changing the hair style, antibiotics and could be recurrent easily if returning to the same traction. Site of folliculitis was in the periphery of hair braids at the site of maximal traction. This could explain the mechanical cause rather than the bacterial causation due to sparing the nearby hair follicles from being affected.

### References

1. Habif TP. Bacterial infections. In: Clinical Dermatology/A color guide to diagnosis and therapy. 5th ed. Mosby Inc. 2010; 9:351-358.
2. Berker DAR, Messenger AG & Sinclair RD. Disorders of hair. In: Tony Burns, Stephen Breathnach, Neil Cox and Christopher Griffiths (eds). Rook Wilkinson Textbook of Dermatology. 8th ed. Singapore: Blackwell Scientific Publications, 2010; 66.52-66.53.
3. Fox GN, Stausmire JM, Mehregan DR. Traction Folliculitis; an underreported entity. *Cutis*. 2007 Jan; 79(1): 26-30.
4. Urbina F, Sudy E, Barros M. Traction Folliculitis: 6 cases caused by different type of hair style that pull on the hair. *Actas Dermosifiliogr*. 2009 Jul-Aug; 100(6): 503-6.



**Figure 1** Distribution of cases according to the residency.

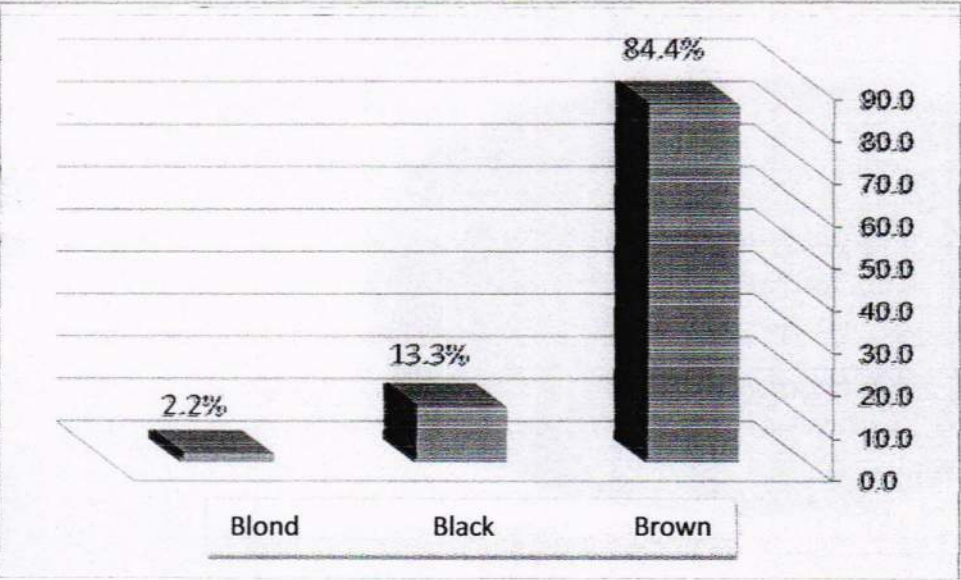


Figure 2 Distribution of cases according to the hair color

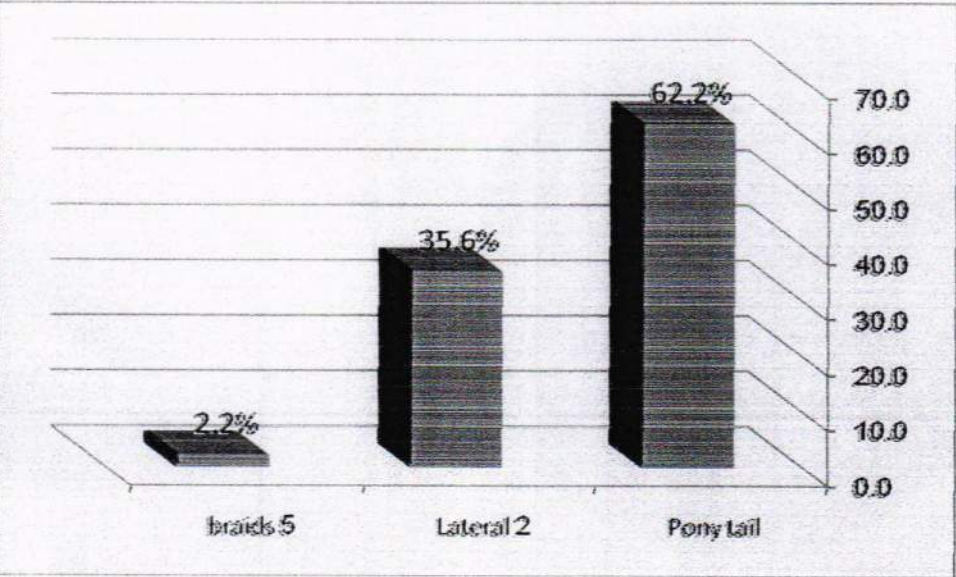

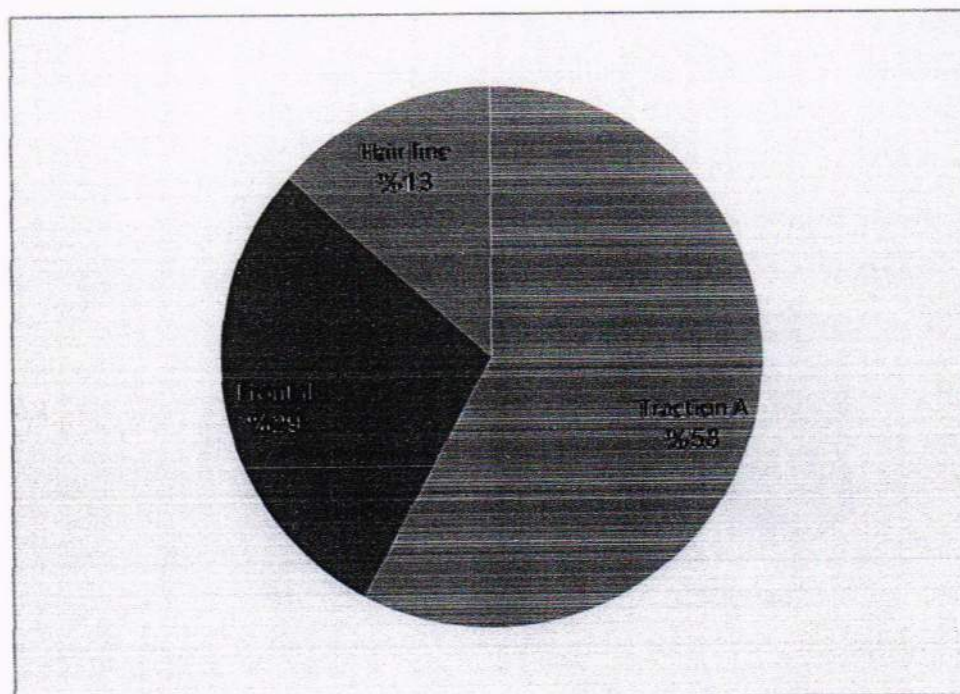


Figure 3 Distribution of cases according to the hair styles





**Figure 4** Distribution of cases according to the hair loss



**Figure 5** Distribution of cases according to the site of traction

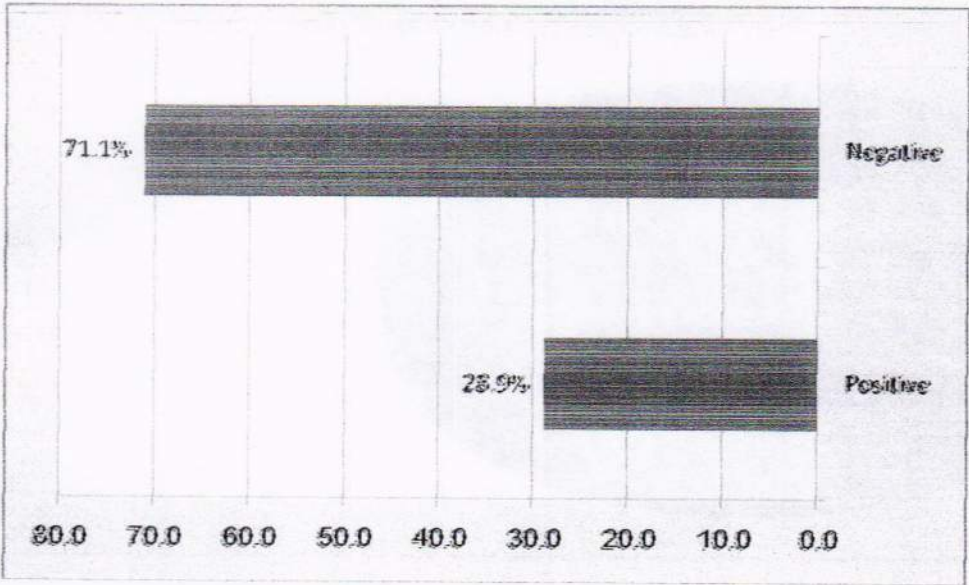


Figure 6 Distribution of cases according to the similar history

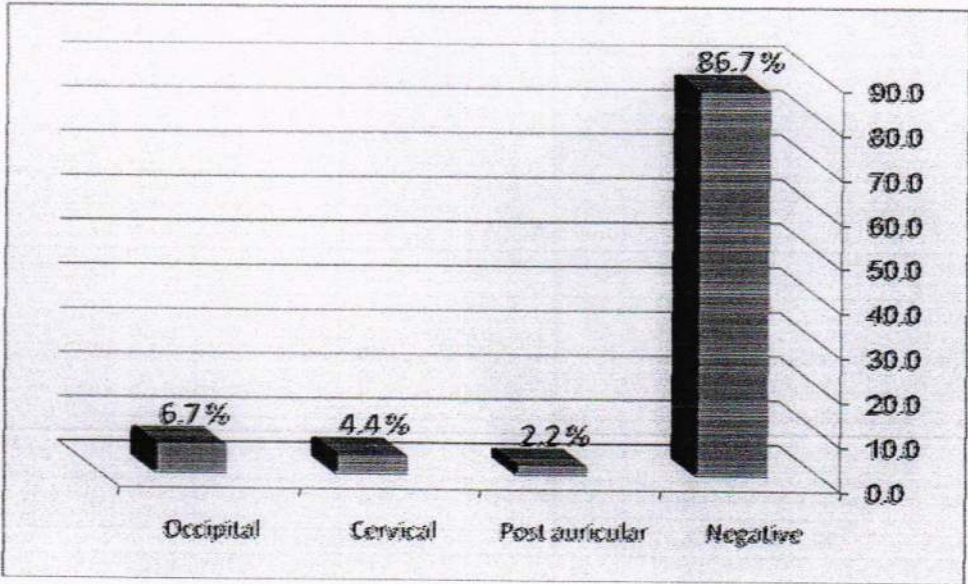




Figure 7 Distribution of cases according to the presence of lymph nodes





**Figure 8** Distribution of cases according to the results of culture & sensitivity



**Figure 9** Distribution of cases according to complain of itching

التهاب بصيلات الشعر في فروة الرأس من جراء السحب.

عند الأطفال الإناث (في العراق)

د. أسامه محمد الجبوري: بور د (بكتوراه) في الأمراض الجلدية والتناسلية (كلية الطب-جامعة تكريت).

## الخلاصة

التهاب بصيلة الشعر قد يكون سببه الإصابة بالبكتريا، التخدش الكيماوي أو الشدة الفيزاوية على الشعر. تم التعرف على سلسلة من حالات التهاب بصيلات الشعر في فروة الرأس عند الأطفال العراقيين الإناث (غير مسجلة سابقاً)، كل الحالات كان عندها تاريخ مسبق في سحب الشعر المفرط. أهداف البحث: لغرض تقييم ووصف حالة جديده من التهاب بصيلات الشعر في فروة الرأس وتمييزها عن الحالة المعروفة بـ (الحاصة) المسببة من جراء سحب الشعر. سلسلة من 45 مريضاً مصابين بالتهاب بصيلات الشعر بسبب السحب المفرط على فروة الرأس تم ملاحظتهم للفترة بين تشرين الاول 2008 إلى تشرين الأول 2011 بإستعمال طريقة الملاحظة. كان التهاب بصيلات الشعر في فروة الرأس يشمل قشور صغيرة، إحمرار حول بصيلات الشعر يرافقه قوالب تحيط بالشعر. أعراض المرض كانت الألم عند تمشيط الشعر، حكة فروة الرأس، وكان هناك نسبة قليلة 15.6% من الحالات لديها تضخم في الغدد اللمفاوية. لم تكن هناك حالات إصابة للجلد في المناطق القريبة (الوجه والرقبة). المرض من أول وهلة يشابه الإصابة بقمل الرأس لكن ليس هناك بيوض القمل كل الحالات كانت بين 1.5-11 سنة. كان لون الشعر بنياً في 84.5% من الحالات، أسود في 13.3% وأشقر في حالة واحدة 2.2%. كانت تسريحة الشعر (ذيل الحصان) في 62.2%، جديلتين جانبيتين في 35.6% و 5 جدائل خلفية في واحدة من الحالات 2.2%. لم يكن بين المرضى من لديه شعر مجعد. هذه الحالة تم تجاوزها ومعالجتها بتغيير تسريحة الشعر وتقليل السحب على الشعر وباستخدام الصوابين المعقمة وقد يتطلب الأمر استعمال المضادات الحيوية لفترة اسبوع واحد.

إنها حالة مرضية لم تسجل سابقاً وكانت قد تشخص خطأ على انها قمل الرأس. كانت المجموعه العمرية بصورة رئيسية سن قبل المدرسة في 73.3% من الحالات وسن الدراسة الابتدائية في 26.7% من الحالات. يمكن تفسير الإصابة بمثل هذا الالتهاب ببصيلات الشعر بسبب السحب الميكانيكي للشعر الذي يؤدي الى التهاب بصيلات الشعر والذي ظهر أنه لا يحوي على البكتريا المرضية إلا في حالات قليلة التي قد تكون مسبباً ثانوياً جراء الحك بالأظافر الملوثة.