

Morphological changes of the placentae from anaemic pregnant women associated with intrauterine growth restriction

Morphological changes of the placentae from anaemic pregnant women associated with intrauterine growth restriction

Mareb H. Ahmed, Dr. Abduljaber Y. Alhubaity

Abstract

Placentae from 50 pregnant women were collected from Albatool Obstetrics and Gynecology Teaching Hospital in Mosul-Iraq. Thirty of them belonged to anaemic pregnant women associated with intrauterine growth restriction (IUGR), while the other 20 belonged to uncomplicated pregnancy (as a control group). The parameters studied were mean gestational age, birth weight of babies, mean placental weight, diameter, surface area, and mean placental volume. The main findings in the placentae from anaemic women were compared to the control group.

Results reveal that there is a significant decrease in mean birth weight, mean placental weight, diameter, surface area and mean volume of the placentae in anaemia of pregnancy group associated with IUGR as compared with control group.

Alterations in various parameters may be due to compensatory phenomena to fulfill the demand of O₂ to fetus, subsequently affecting the growing fetus. Appropriate precautions if taken during pregnancy, complications due to anaemia can be reduced.

In conclusion, this study demonstrated that severe anaemia in pregnant women alters the placental morphology, leading to fetal growth restriction and prompt treatment of anaemia must be taken to improve placental growth and a favorable obstetric outcome.

Key words: Anaemia, placenta, morphology, growth restriction.

Introduction

A nemia is a common disorder during pregnancy, with an incidence of

20 to 40% during pregnancy, observed more frequently in developing countries (1,2). It increases the maternal, fetal and neonatal mortality and morbidity (3), and according to WHO (2011) (4), pregnancy anaemia

Morphological changes of the placentae from anaemic pregnant women associated with intrauterine growth restriction

exists if hemoglobin is lower than 11 gm /dl and hematocrit lower than 31%. Anaemia during pregnancy usually develops due to lack of iron, which may be due to nutritional deficiency or increased demand for oxygen during pregnancy (5). Rough estimation of hematological status of pregnant women's imply checking of Hb and Htc values, that have been modulated by the degree of pregnant woman blood volume enlargement(6). 87% of women have nutritional anaemia in pregnancy due to iron deficiency (7).

When pregnancy is complicated by anaemia, many morphological changes are seen in placentae. Maternal anaemia and malnutrition having significant association with fetal growth restriction (8).

Human placenta is a flattened discoidal mass. The outline is circular or oval with an average weight of about 500 grams and average diameter of about 18 cm. It has two surfaces, the maternal decidua basalis which appears

Material and Methods

This study was conducted at the Department of Anatomy, Medical College, Mousl University. Placentae were collected immediately after

as rough, reddish, and is subdivided by grooves into irregular areas known as cotyledons, and the fetal part (chorionic frondosum) which is smooth and covered by amnion having the umbilical cord attached near to its centre (9). The trophoblast is the basic parenchyma of the placenta, as it gives fine finger like projections called primary villi, and with progressive development secondary and tertiary villi are formed too (10). Development of the placenta is affected by anaemia and low hemoglobin concentration during pregnancy is associated with an increased risk of low birth weight baby (11).

In spite of the extensive research on the effects of maternal anaemia on the fetus and placentae, the observations were contradictory, thus the present work was conducted to assess the morphological changes in placentae associated with maternal anaemia and intrauterine growth restriction.

delivery from labour room and operation theatre of Albatool Teaching Hospital. Thirty placentae were from cases of maternal anaemia (Hb < 10g/dl) associated with intrauterine growth restriction without any complications or diseases like pre-

Morphological changes of the placentae from anaemic pregnant women associated with intrauterine growth restriction

eclampsia or diabetes, and the other 20 belonged to normal pregnancy (control group). All the deliveries occurred at full term (37-40 weeks). All mothers were between 20 to 35 years old and some were primigravida and others multigravida. Gestational age was calculated according to last menstrual period or by early ultrasound examination. All pregnancies were terminated for suspicion of IUGR either by induced vaginal delivery or by cesarean section. IUGR was confirmed in each case clinically as well as by sonar. We included IUGR due to anaemia and excluded IUGR due to other causes. The criteria considered for the growth-restricted pregnancy were fetuses with a weight of less than tenth percentile. The data were collected on the prescribed performa. The weight of the newborn and gestational age were recorded within the first hour after delivery.

Just after the delivery, the umbilical cord was clamped, close to the placental insertion point. Membranes were trimmed, placentae were washed out under running tap water until the appearance of clear wash out water, examined immediately and then tagged with code numbers., Superficial vessels were drained of all blood and surface dried with the help

of blotting papers. Each placenta was inspected for any abnormality such as accessory lobe or Bi-lobed placenta and recorded.

A detailed gross examination of the placentae was done with emphasis on the following features:

1- Weight of the placentae was taken in grams (gm) directly by placing the placenta over standardized weighing machine.

2- Diameter: The placenta was placed in a dry metallic tray after trimming and mopping keeping the maternal surface facing up ward, measured twice up to the nearest 0.5 cm. At first, the maximum diameter (d1) was measured with a metallic scale. Then second diameter (d2) was recorded at right angles to the first one. The mean (d) of the two measurements was considered as the diameter of placenta.

3- Surface area of the placenta was estimated in cm². It was recorded by cutting out its shape on a piece of plastic sheet which was mapped on a graph sheet to calculate the area, assuming the placenta as a perfect circle, the mean radius 'r' was estimated from the surface area.

Area: The placental area was calculated by using equation:

$$A = (\pi/4) \times d1 \times d2 \text{ (12).}$$

Morphological changes of the placentae from anaemic pregnant women associated with intrauterine growth restriction

Formula for Surface area of the placenta = πr^2 , where:

$\pi=3.14$, r- Radius of the placenta.

5- Thickness: Each placenta was placed on its fetal surface. Thickness was measured by inserting a calibrated Knitting needle (Vernier caliber) at five points of each placenta. To have uniform five points in each placenta, the placenta was divided into three zones by two arbitrary circles on the placental maternal surface, which cut the radius of the placenta into three equal lengths from center to periphery. One thickness was measured from the center of the central zone, two from middle and two from peripheral zone. The peripheral points were taken within the outer zone on a line perpendicular to the previous imaginary line. The mean of the five measurements was calculated and measured in centimeter, with accuracy

of 0.1 cm and considered as the thickness of the placenta.

6- Volume: The volume of placenta was calculated and estimated by the help of water displacement method. A four-litre graded cylindrical plastic bucket was taken which has an attached draining tube. The placenta was placed in it .The displaced water was collected in a pot and measured in a graded cylinder marked in milliliters (ml).

Statistical analysis

Data entry were done by Microsoft excel 2013 and analyzed statistically by student T –test using graph pad prism version 6.01 and data expressed as mean \pm standard deviation. P- value < 0.05 was considered to be statistically significant.

Results

The mean age of the control group was 28.05 ± 1.03 years compared to the mean age in study group 29.70 ± 0.78 and the difference is not significant (P value > 0.05) see graph (1).

The most frequent macroscopic abnormality encountered in IUGR placentae was placental fibrosis in around 26.67% on the maternal surface of the placenta compared to 10% of controls (Fig1). Hemorrhage was seen in 23.33% in IUGR compared to 5% in the control group (Fig2).

Morphological changes of the placentae from anaemic pregnant women associated with intrauterine growth restriction

The mean placental weight from the control group was 491.70 ± 4.12 gm compared to 401.60 ± 5.47 gm in the IUGR group, which is very highly significant ($p < 0.0001$) (Table1, graph 2).

The mean placental diameter from the control group was 17.77 ± 0.45 cm, compared to 16.11 ± 0.38 cm in the IUGR associated with anaemia, which is highly significant ($p < 0.001$) (Table1, graph 3).

The mean placental volume from the control group was 447.0 ± 9.65 ml compared to 380.0 ± 8.25 ml from the IUGR group which is very highly significant ($p < 0.0001$) (Table 1, graph 4).

The mean thickness of placenta from the control group was 2.78 ± 0.08 cm, compared to 2.06 ± 0.07 cm from the IUGR group which is very highly significant ($p < 0.0001$) (Table1, graph 5).

Discussion

Many studies have been conducted on examination of placenta and foetal outcome in anaemia with IUGR pregnancies but very few of them have used parameters, which are comparable with each other, thus making its reliability difficult.

The placental surface area from the control group was 250.90 ± 12.21 cm² compared to 207.0 ± 9.93 cm² from the IUGR group, which is highly significant ($p < 0.001$) (Table1, graph 6).

The mean gestational age at delivery was 38.90 ± 0.25 weeks in the control group, which is higher and statistically significant than the in study group 37.60 ± 0.14 weeks ($p < 0.001$), (graph 7).

The mean birth weight of the newborn babies delivered from the control women was 3285 ± 68.27 gm, while in the women with anaemia & IUGR, the mean birth weight of their babies was 2093 ± 62.41 gm. The difference is highly significant ($p < 0.001$) indicating a significant association of low birth weight with the IUGR (graph 8).

Anaemia in female during pregnancy is very common, and leads to maternal hypoxia. Anaemia also exerts serious changes on the maternal circulatory system and has severe effects both on mother and fetus. Growth of fetus is related with

Morphological changes of the placentae from anaemic pregnant women associated with intrauterine growth restriction

development of placenta, because placenta causes transfer of nutrients as well as oxygen from mother to fetus. Hypoxia causes morphological changes in placental weight, diameter, thickness of placentae with increased low birth weight baby and premature delivery. Placental anomalies therefore can be an 'early warning points' about fetal problems (10). The assessment of placenta thus becomes essential in high-risk pregnancy as most of the perinatal fetal deaths were related to insufficient oxygen supply in utero. Placenta plays an essential role in transport of oxygen to the fetus and essential for healthy fetal outcome. Therefore, study of placenta is a valuable tool in predicting the outcome of future pregnancies and their management.

The gross finding of fibrosis in the study group was also reported by Soni et al.,¹² who mentioned that the incidence of fibrosis increases with the increase in the severity of anaemia (10).

The present study shows that mean placental weight is significantly reduced in case of placentae of pregnancy associated with anaemia and IUGR group as compared to control group. Similar findings noted that the

placental weight of the severely anaemic mothers were significantly lower than control (13,14), explained that small placenta of severely anaemic mother is due to retarded growth of placenta with decrease in total placental DNA suggesting a decrease in cell number and reduction in size, where there is early stop of cell division in anaemia.

Maternal anaemia represents an independent risk factor for abnormal placental growth (15) and hypertrophy (16), but as pregnancy advances, placental growth restriction and development of small, hypotrophic placenta occur (17). Contradictory findings of heavier placenta was given by Godfrey et al., explaining that maternal anaemia causes inadequate oxygenation of the feto-placental unit and this in turn raises the physiological response resulting in compensatory placental hypertrophy, but however in severe anaemia the placenta is affected so much(18).

In our study, the mean birth weight is significantly reduced in IUGR pregnancy with anaemia 2093 ± 62.41 gm compared to 3285 ± 68.27 gm in the control group. Our findings correlate with those of Chavan et al., (19) who noticed that the birth weight

Morphological changes of the placentae from anaemic pregnant women associated with intrauterine growth restriction

and head circumference of the newborn was significantly reduced in anaemic group compared to control group. Prematurity and low birth weight is increased in severe anaemia, which is attributed to early maturity of placenta, because of hypoxia (10). Anaemia can be a direct cause of deterioration of fetal growth due to lack of oxygen flow to placental tissue or can be an indirect indicator of maternal nutrition deficit (20).

There are opposite data from developing countries where, among well-nourished maternal population, lower iron status of expecting mothers was associated with a higher birth weight and a longer duration of pregnancy (21).

Young et al., suggested that the diminished supply of fetal and placental tissue with iron, will modifies expression of placental transferrin receptors due to fetal and placental needs (22). Several studies implicated that maternal pregnancy anaemia represents a significant risk factor for lower birth weight (23) and results in earlier delivery (24), this explains our finding of lower gestational age in the anaemic associated IUGR group. Maternal anaemia caused by deficiency of iron

in early pregnancy is double-sized risk for preterm delivery of small birth weight baby (20).

In the present study, the mean placental diameter from the control group was 17.77 ± 0.45 cm, compared to 16.11 ± 0.38 cm in the anaemia & IUGR group, which is highly significant ($p < 0.001$), while the diameter was found to be greater in anaemic groups 18.80 ± 1.96 cm than the control groups 15.60 ± 0.74 cm and was significant ($p < 0.001$) in other study (25). The possible explanation that the maternal anaemia result in fetal hypoxemia and stimulates placental growth. In anaemia, significant changes both in gross morphology and in the structure of the placenta can occur, which is contradictory to the observations of the present study, our explanation is that the present study included moderate to severe anaemia that leads to intrauterine growth restriction.

The significant reduction in placental surface area in anaemic and IUGR group as compared to control pregnancies in the present study, is in conflict with the observation of Begum et al who found the placental surface area were highest 235.12 cm^2 in moderate anaemia as compared to

Morphological changes of the placentae from anaemic pregnant women associated with intrauterine growth restriction

control group 219.26 cm²(25). The study of Praveen et al., indicated that sickle cell anaemia adversely affected gross placental parameters. The mean weight, the mean volume and the placental surface was found lower. This might be the probable reason behind worst foetal outcome in mothers with sickle cell disease (26).

In the present study, the mean placental volume is lower 380.0 ± 8.25 ml in study group than in normal pregnancy group 447.0 ± 9.65 ml contradictory to our finding, other studies found volume of the placenta in group control 444.00±38.37 and increase with antenatal anaemia of mothers to 485.38±24.62 ml (27, 28).

Conclusion

At last, we can conclude that the birth weight of babies and placental weight in pregnancy complicated by anaemia and IUGR are less than that of the normal pregnancies. The mean surface area, thickness and volume of the placenta is also decreased in the study group than normal

References

1. Montoya RJ, Castelazo ME, Valerio CE, Velázquez CG, Nava MD, Escárcega PJ, Montoya CJ, Pichardo VG, Maldonado AA, Santana GH, Fajardo DS (2012).

Placental hypertrophy associated with maternal anaemia, which is probably a compensatory physiological response to ensure adequate oxygen supply to the fetus. Lelic et al., found no significant difference comparing total placental volume in anaemic with placentae from high altitude pregnancies (14), that have been considered as a preplacental hypoxic condition (16) and mentioned that maternal anaemia had no significant influence on placental structures, particularly on terminal villi, but the morphometric characteristic of placental tissue, pregnancy course and outcome can be influenced with the severity of maternal anaemia.

Pregnancies. The foetal weight and gestational age is also decreased. Therefore, it can be concluded that severe anaemia in pregnancy alters the placental morphology that, in turn, affects the weight of the fetus causing fetal growth restriction

Review by expert group in the diagnosis and treatment of anemia in pregnant women. *Ginecol Obstet Mex*; 80(9):563-580.

Morphological changes of the placentae from anaemic pregnant women associated with intrauterine growth restriction

2. AlQuaiz, A. M., Gad Mohamed, A., Khoja, T. A. M., AlSharif, A., Shaikh, S. A., Al Mane, H., Hammad, D (2013). Prevalence of Anaemia and Associated Factors in Child Bearing Age Women in Riyadh, Saudi Arabia. *Journal of Nutrition and Metabolism*; 2013:1-8.
3. Dr Samar K Basu. Anaemia in pregnancy. Health matter, [Monograph on the internet] G M Modi Hospital. [Cited on 2012 Oct 8]. Available from: <http://delhimedicalcouncil.nic.in/Anaemiainpregnancy.pdf>
4. WHO (2011); Hemoglobin concentrations for the diagnosis of anaemia and assessment of severity. *Vitamin and Mineral Nutrition Information System*, Geneva, World Health Organization; VMNIS 1- 5.
5. Breymann C, Bian XM, Blanco-Capito LR, Chong C, Mahmud G, Rehman R(2011). Expert recommendations for the diagnosis and treatment of iron-deficiency anemia during pregnancy and the postpartum period in the Asia-Pacific region. *J Perinat Med*; 39(2):113-121.
6. Dizdarević-Stojkanović J (2007). Hematopoetska oboljenja u trudnoći In: Balić A. ed, *Perinatologija*, Univerzitet u Tuzli.:474-486
7. Rameshwari M. Nisty, Gangambika M. Nisty, Amrutha Patil (2014) “Maternal and Fetal Outcome in Pregnancy with Severe Anaemia”. *Journal of Evolution of Medical and Dental Sciences*; 3(15): 4132-4136.
8. Sawant LD, Venkat S (2013). Comparative Analysis of Normal versus Fetal Growth Restriction in Pregnancy: The Significance of Maternal Body Mass Index, Nutritional Status, Anaemia, and Ultrasonography Screening. *Int J Reprod Med*; 2013: Article ID 671954, 6 pages
9. Moshiri M, Zaidi SF, Robinson TJ, Bhargava P, Siebert JR, Dubinsky TJ, Katz DS (2014)=. Comprehensive imaging review of abnormalities of the umbilical cord. *Radiographics* ; 34(1):179-196.

Morphological changes of the placentae from anaemic pregnant women associated with intrauterine growth restriction

10. Soni R, Sharma V, Nair S (2013). Study of changes in placental morphology fate of fetus in anaemic mothers. *Journal of Evolution of Medical and Dental Sciences*; 2 (31):5830-5845.
11. Kumar JK, Asha N, Murthy DS, Sujatha MS, Manjunath VG. (2013). Maternal Anaemia in Various Trimesters and its Effect on Newborn Weight and Maturity: An Observational Study. *Int J Prev Med* ; 4(2): 193-199.
12. Pryse-Davies J., Beazley J.M., Leach G (1973). A study of placental size and chorioamnionitis in a consecutive series of hospital deliveries. *Br. J. Obstet. Gynaecol* ; 80 : 246-251.
13. Rusia U, Bhatia A, Kapoor S, Madan N, Nair V, Sood SK (1988). Placental morphology & histochemistry in iron deficiency anaemia. *Indian J Med Res*; 87: 468-474.
14. Lelic M, Bogdanovic G, Ramic S, Brkicevic E (2014). Influence of Maternal Anaemia During Pregnancy on Placenta and Newborns. *Med Arh.* 68(3): 184-187.
15. Laflamme EM (2011). Maternal Hemoglobin Concentration and Pregnancy Outcome: A Study of the Effects of Elevation in El Alto, Bolivia. *McGill Journal of Medicine* : MJM; 13(1):47-55.
16. Mayhew TM (2003). Changes in fetal capillaries during preplacental hypoxia: growth, shape remodeling and villous capillarization in placentae from high altitude pregnancies. *Placenta* ; 234 (2-3): 191-198.
17. Reshetnikova OS, Burton GJ, Teleshova OV (1995). Placental histomorphometry and morphometric diffusing capacity of the villous membrane in pregnancies complicated by maternal iron-deficiency anaemia. *Am J Obstet Gynecol*; 173(31): 724-727.
18. Godfrey KM, Redman CW, Barker DJ, Osmond C (1991). The effect of maternal anaemia and iron deficiency on the ratio of fetal weight to placental weight. *Br J Obstet Gynaecol*; 98 (9):886-891.

Morphological changes of the placentae from anaemic pregnant women associated with intrauterine growth restriction

- pregnant adolescents. *Placenta* ; 31(11):1010-1014.
19. Chavan, P R; Selukar, M S; Sudke, G B; Kulkarni, P R (2015). Effect of Maternal Anaemia on Placenta and its Correlation with Fetal Outcome. *Indian Journal of Anatomy* ; 4 (2): 45-50.
20. Yildiz Y, Ozgü E, Unlu SB, Salman B, Eyi EG (2014). The relationship between third trimester maternal hemoglobin and birth weight/length; results from the tertiary center in Turkey. *J Matern Fetal Neonatal Med*; 27(7):729-732.
21. Ervasti M, Sankilampi U, Heinonen S, Punnonen K (2009). Early signs of maternal iron deficiency do not influence the iron status of the newborn, but are associated with higher infant birthweight. *Acta obstetrica et gynecologica Scandinavica*; 88 (1):83-90.
22. Young MF, Pressman E, Foehr ML, McNanley T, Cooper E, Guillet R, Orlando M, McIntyre AW, Lafond J, O'Brien KO (2010). Impact of maternal and neonatal iron status on placental transferrin receptor expression in
23. Ren A, Wang J, Ye RW, Li S, Liu JM, Li Z (2007). Low first-trimester hemoglobin and low birth weight, preterm birth and small for gestational age newborns. *International Journal of Gynecology & Obstetrics*; 98(2):124-128.
24. Kumar JK, Asha N, Murthy DS, Sujatha MS, Manjunath VG (2013). Maternal Anemia in Various Trimesters and its Effect on Newborn Weight and Maturity: An Observational Study. *Int J Prev Med.*; 4(2): 193-199.
25. Begum M, Ara S, Begum S, Kishwara S, Rayhan KA, Hossain A, Nahar A (2009). Big placenta and anaemia in pregnancy. *Journal of Shaheed Suhrawardy Medical College* ; 1(2):17-20.
26. Praveen K, Amit K, Yogesh AS, Shukla CK, Banergee C, Singh T. (2012). Association of sickle cell anaemia in morphology of full term placenta in Chhattisgarh region. *Biomedical Research*; 23(1): 43-46.

Morphological changes of the placentae from anaemic pregnant women associated with intrauterine growth restriction

27. Huang A, Zhang R, Yang Z (2001). Quantitative (stereological) study of placental structures in women with pregnancy iron-deficiency anaemia. *European Journal of Obstetrics & Gynecology and Reproductive Biology* ; 97(1):59-64.
28. Begum M, Nurunnabi AS, Ara S, Begum GN (2011). Effect of Antenatal Anaemia of the Mother on the Volume of the Placenta. *Anwer Khan Modern Medical College Journal*; 2(1):22-25.

**Morphological changes of the placentae from anaemic pregnant women associated with
intrauterine growth restriction**

**Table (1): Placental morphometry between the study
(anaemia &IUGR) and Control groups**

parameters	Anaemia & IUGR N=30	CONTROL N=20	P-value
	Mean ± SD	Mean ± SD	
Placental weight (gm)	401.60 ±5.47	491.70 ± 4.12	<0.0001
Placental surface area (cm)2	207.0 ± 9.93	250.90 ±12.21	<0.001
Placental diameter (cm)	16.11 ± 0.38	17.77 ± 0.45	<0.001
Placental volume (ml)	380.0 ± 8.25	447.0 ± 9.65	<0.0001
Placental thickness (cm)	2.06 ± 0.07	2.78 ± 0.08	<0.0001

Morphological changes of the placentae from anaemic pregnant women associated with intrauterine growth restriction

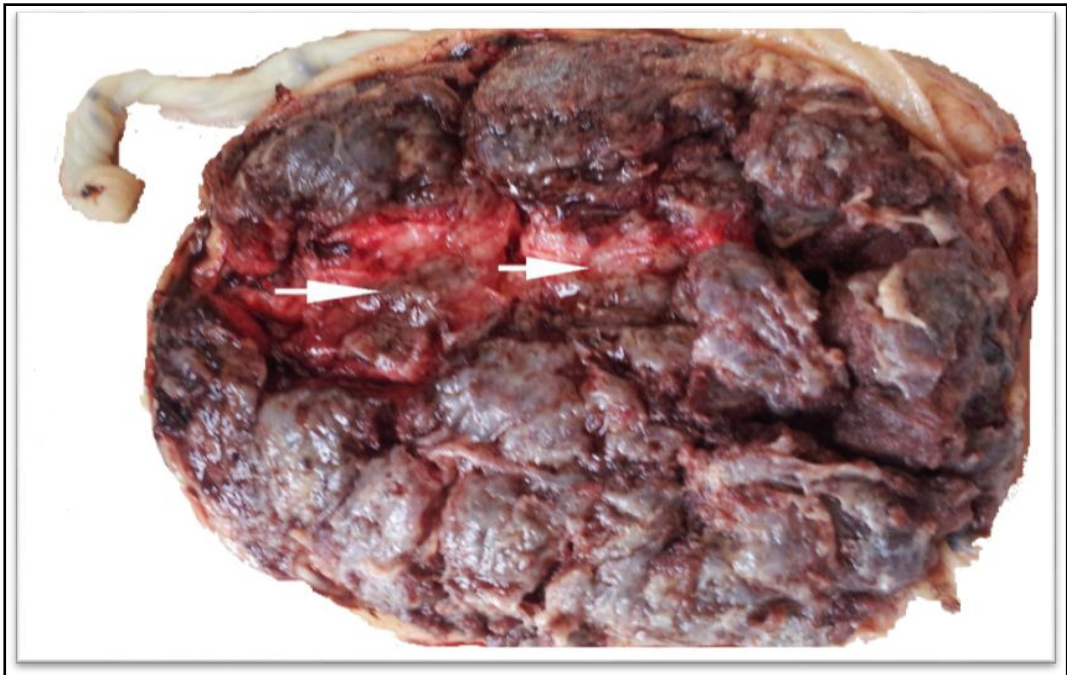
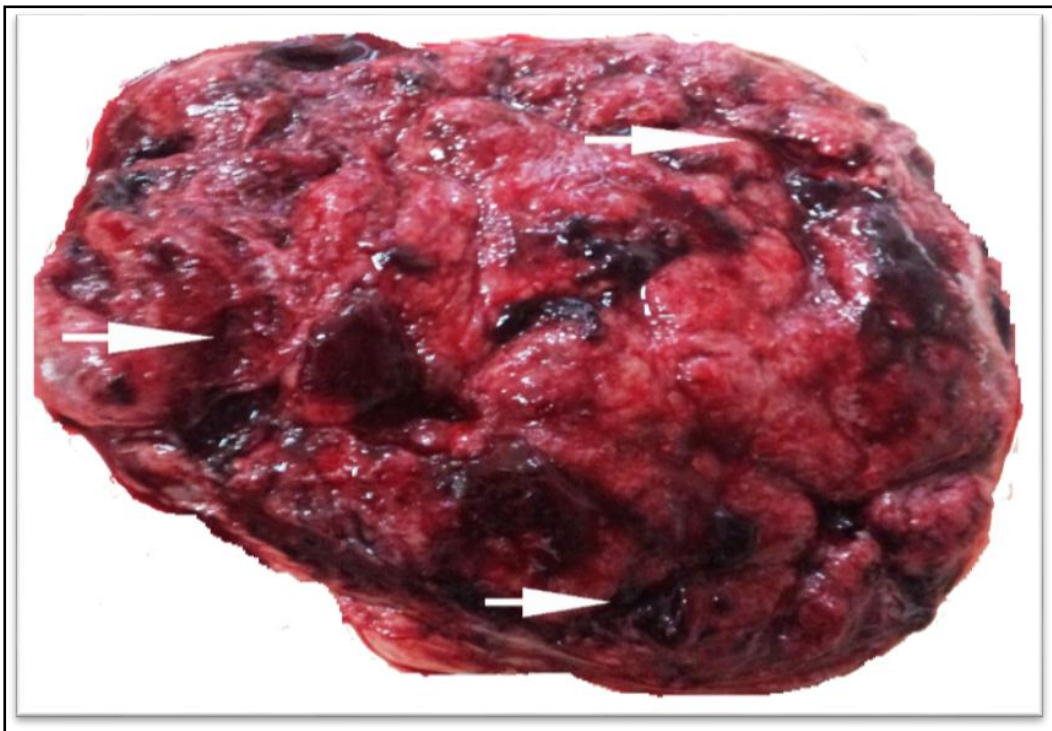

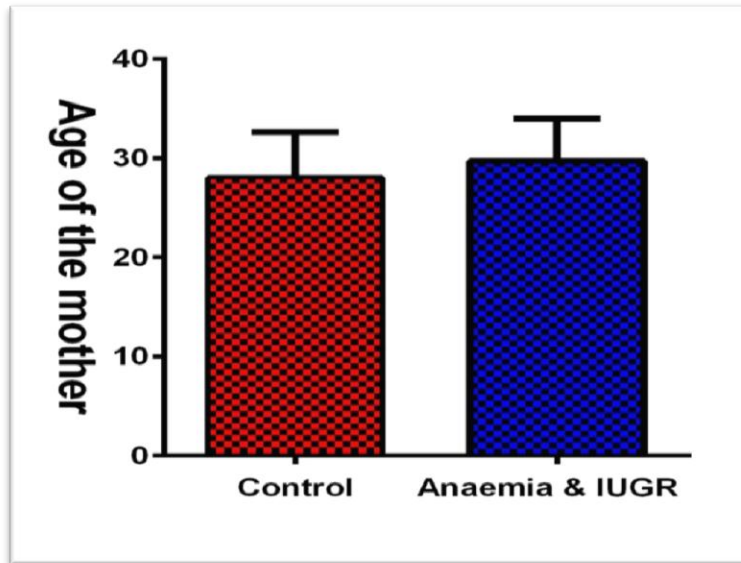
Fig (1): Placenta from the study group (anaemia & IUGR) showing



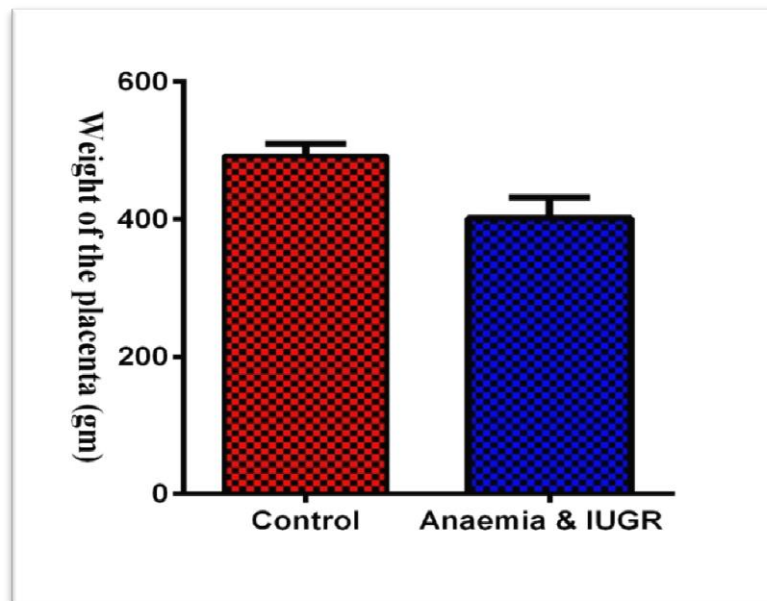
fibrosis (white arrows).

Fig (2): Placenta from the study group (anaemia & IUGR) showing
haemorrhage (white arrows).

Morphological changes of the placentae from anaemic pregnant women associated with intrauterine growth restriction

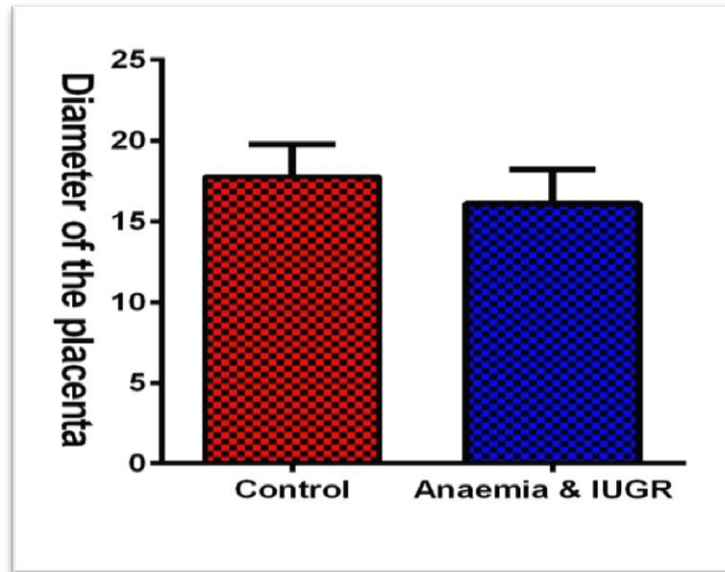


Graph (1): Age of the pregnant mother in the study (anaemia & IUGR) and control groups.

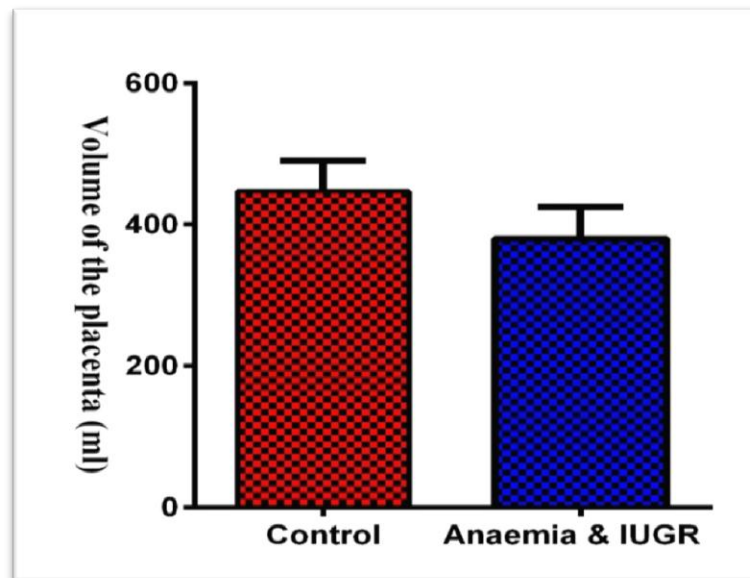


Graph (2): Weight of the placentae in the study (anaemia & IUGR) and control groups

Morphological changes of the placentae from anaemic pregnant women associated with intrauterine growth restriction

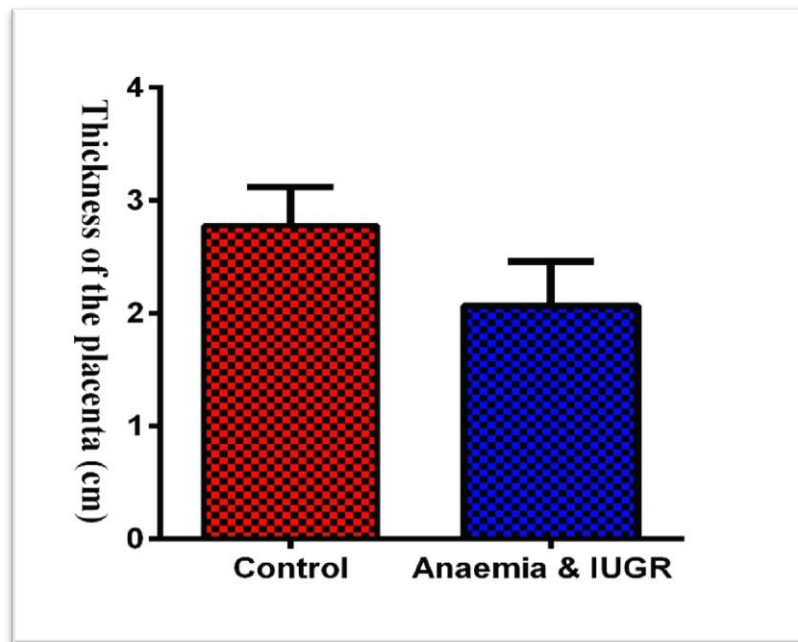


Graph (3): Diameter of the placentae in the study (anaemia &IUGR)and control groups



Graph (4): Volume of the placentae in the study (anaemia &IUGR) and control groups

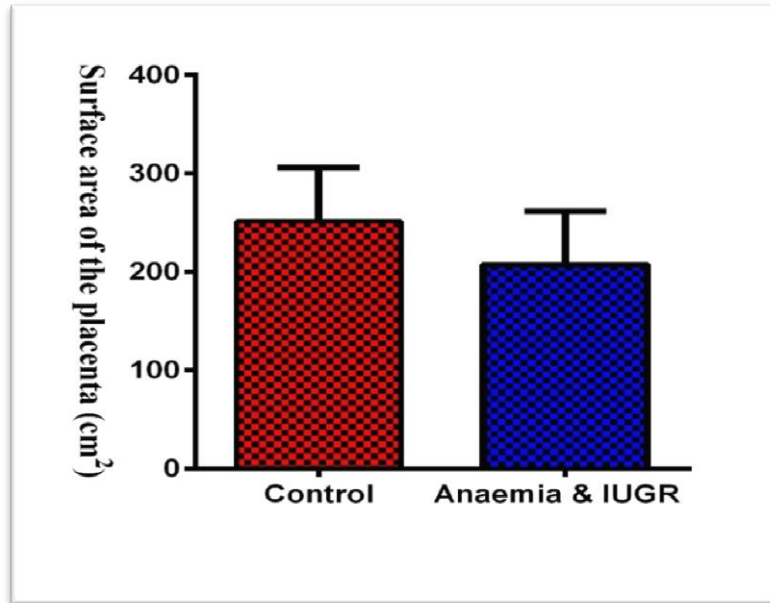
Morphological changes of the placentae from anaemic pregnant women associated with intrauterine growth restriction



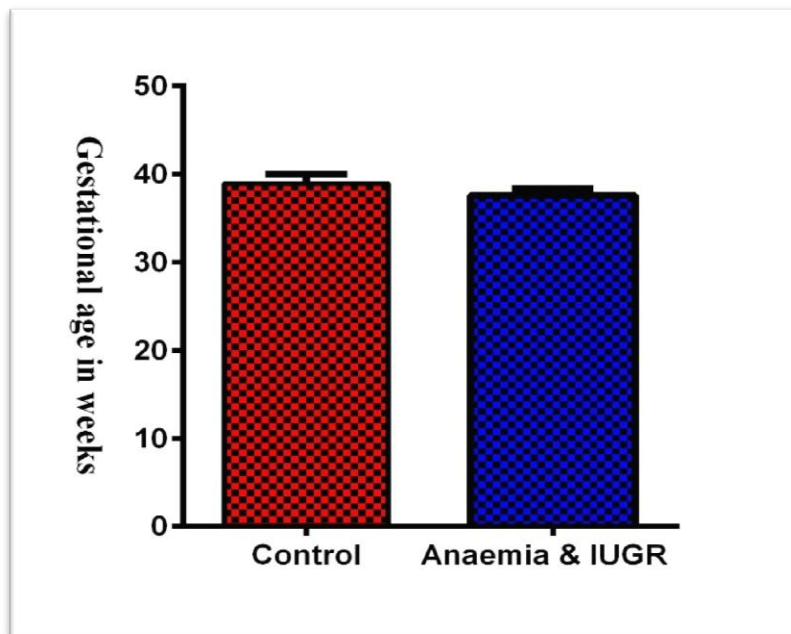
Graph (5):

Thickness of the placentae in the study
(anaemia &IUGR and control groups).

Morphological changes of the placentae from anaemic pregnant women associated with intrauterine growth restriction

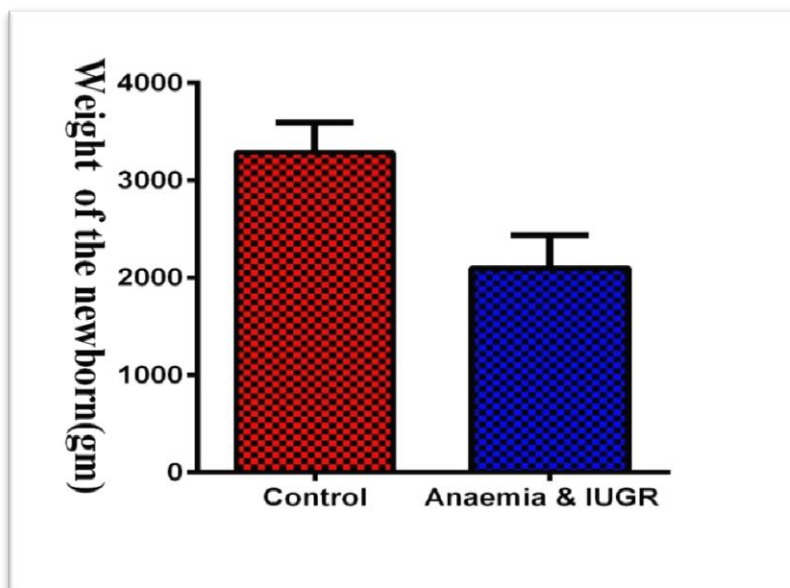


Graph (6): Surface area of the placentae in the study (anaemia & IUGR) and control groups.



Graph (7): Gestational age in the study (anaemia & IUGR) and control groups.

**Morphological changes of the placentae from anaemic pregnant women associated with
intrauterine growth restriction**



Graph (8): Weight of newborn in the study
(anaemia &IUGR) and control groups.