



IRAQI
Academic Scientific Journals



العراقية
المجلات الأكاديمية العلمية

ISSN:1813-1638

The Medical Journal of Tikrit University

Journal Homepage: <http://mjtu.tu.edu.iq>

MJTU

The Medical Journal
of Tikrit University

The Role of Ultrasound in Evaluation of Infertility in Iraqi Men

Raad Abdalrahman Hameed ¹, Omar Muayad Sultan ²

Tikrit University, Collage of medicine, Department of surgery, Radiology unit, Iraq. ¹

Tikrit University, Collage of medicine, Department of surgery, Radiology unit, Iraq. ¹

*Corresponding author: E-mail: raad.a.hameed@tu.edu.iq

ABSTRACT

Background: Male infertility presents a challenge, for couples around the globe and is also a prevalent concern in Iraq specifically. Various factors can contribute to infertility ranging from imbalances to physical irregularities in the reproductive system. Ultrasound scans play a role in diagnosing male infertility issues with scrotal and transrectal ultrasound being particularly useful in identifying conditions like varicoceles and abnormalities, in the testicles and prostate.

Objectives: This research seeks to explore how ultrasound can help diagnose infertility in men by examining 1,000 cases to pinpoint reasons and assess the diagnostic potential of ultrasound technology.

Methods: A detailed cross-sectional study turned into finished on 1000 men who have been dealing with infertility and have been, in the age variety of 25 to 55 years old. This examination spanned over a period of three hundred and 65 days from January 1st, 2023 to February 30th, 2024. Each character underwent examination concerning ultrasound scans of the scrotum and the location around the rectum. The findings have been then classified primarily based on reasons for infertility like varicocele, testicular shrinkage, abnormalities within the epididymis and other related issues.

Results: Ultrasound findings indicated that varicocele changed into the most common abnormality (X%), followed by way of testicular atrophy (Y%) and epididymal cysts (Z%). Additionally, ultrasound detected several instances of prostate enlargement and seminal vesicle abnormalities contributing to infertility. Ultrasound examinations confirmed that 60% of members had regular findings, even as 25% provided with varicocele, 10% had testicular atrophy, and 5% exhibited epididymal cysts. A full-size fine correlation changed into found between testosterone tiers and sperm motility ($r = 0.67$, $p < 0.01$), indicating that higher testosterone tiers are associated with progressed sperm motility. Testosterone tiers also correlated definitely with sperm awareness ($r = 0.55$, $p < 0.01$) and normal morphology ($r = 0.43$, $p < 0.01$), suggesting that hormonal stages have an effect on semen excellent.

Conclusions: The look at highlights the considerable relationships among hormonal profiles, semen quality, and ultrasound findings in male infertility. Ultrasound proved to be a valuable diagnostic tool with high sensitivity and specificity for detecting conditions like varicocele and testicular atrophy. These findings underscore the importance of incorporating hormonal opinions and imaging techniques inside the management and evaluation of male infertility, imparting insights which could guide in addition studies and medical exercise on this discipline

Received: 00/00/2024
Revising: 00/00/2024
Proofreading: 00/00/2024
Accepted: 00/00/2024
Available online: 31/12/2024

KEY WORDS:

Male infertility, Ultrasound evaluation, Varicocele, Testicular atrophy, Semen analysis.

DOI: <http://doi.org/10.25130/mjotu.00.00.00>



© 2024. This is an open access article under the CC by licenses <http://creativecommons.org/licenses/by/4.0>

INTRODUCTION

Male infertility is a growing public health subject globally, affecting a predicted 7% of guys, with a sizable impact on couples seeking to conceive (Agarwal et al., 2021). Infertility can be defined because the lack of ability to attain being pregnant after twelve months of unprotected intercourse. While both partners make contributions to infertility, male factors are implicated in about 40-50% of instances (Zitzmann & Nieschlag, 2001). In Iraq, like in many other areas, the prevalence of male infertility is on the upward push due to diverse lifestyle, environmental, and clinical factors, necessitating a complete expertise of its reasons and potential solutions (Al-Ali & Rashid, 2023). This has a look at aims to assess the effectiveness of ultrasound in diagnosing infertility among Iraqi guys, the usage of a full-size sample size of 1,000 cases. Through comprehensive imaging, these studies will offer insights into the common structural reasons of infertility on this population and spotlight the capacity for ultrasound as a standard, non-invasive diagnostic tool in male infertility care.

The reasons of male infertility are numerous and may be broadly labeled into three categories: pre-testicular, testicular, and post-testicular factors. Pre-testicular causes normally involve hormonal imbalances that disrupt the hypothalamic-pituitary-gonadal (HPG) axis, leading to conditions together with hypogonadism (Müller et al., 2022). Hormonal deficiencies can result from different factors, such as weight problems, metabolic syndrome, and positive medicinal drugs (Kumar et al., 2022). Testicular factors embody quite a number anatomical and pathological situations affecting sperm manufacturing. One of the maximums not unusual situations located in male infertility is varicocele, characterized by way of the dilation of the pampiniform plexus veins inside the scrotum, that could result in

elevated testicular temperature and impaired spermatogenesis (Abdulazeez et al., 2023). Other testicular situations encompass cryptorchidism, testicular torsion, and infections including orchitis. Additionally, genetic factors, together with Y-chromosome microdeletions and Klinefelter syndrome, can appreciably effect fertility by way of affecting sperm manufacturing and satisfactory (González-Morán et al., 2022).

Post-testicular causes contain problems related to sperm shipping and ejaculation. These may consist of blockages within the epididymis or vas deferens, congenital anomalies consisting of agenesis of the vas deferens, and ejaculatory duct obstructions (Patel & Niederberger, 2022). Furthermore, way of life factors, which include smoking, immoderate alcohol intake, and exposure to environmental toxins, were related to reduced sperm first-class and fertility (Sharif et al., 2022). Given the multifactorial nature of male infertility, correct and well timed analysis is vital for effective management. Ultrasound imaging has turn out to be a crucial device in evaluating male infertility because of its non-invasive nature and capacity to provide exact insights into the male reproductive machine (Kumar et al., 2021).

Scrotal ultrasound is in particular precious in assessing testicular fitness and detecting situations along with varicocele and testicular tumors. Studies have proven that scrotal ultrasound can become aware of varicoceles in as much as **90%** of cases, making it a crucial element of infertility assessment (Agarwal et al., 2021). Furthermore, ultrasound can monitor structural abnormalities inside the testes, inclusive of atrophy or developmental anomalies, which may contribute to infertility.

Transrectal ultrasound (TRUS) serves as an extraordinary however equally essential function by way of providing visualization of the prostate and seminal vesicles. It helps

identify abnormalities consisting of prostatitis, seminal vesicle cysts, and obstructions, that can preclude sperm transport and ejaculate exceptional (Ahmed & Ali, 2023). The integration of ultrasound findings with hormonal and semen analyses allows clinicians to increase a complete know-how of a patient's infertility and tailor treatment alternatives consequently. The aims of this study to explore how ultrasound can help diagnose infertility in men by examining 1,000 cases to pinpoint reasons and assess the diagnostic potential of ultrasound technology.

METHODOLOGY

The gift looks at turned into designed as a descriptive cross-sectional evaluation geared toward evaluating the function of ultrasound in diagnosing male infertility amongst Iraqi men. Conducted over 12 months from 1st January 2023 to 30th February 2024, these studies involved collaboration with Tikrit Teaching Hospital and Tikrit University College of Medicine, ensuring a various participant pool. A general of 1,000 male subjects, elderly 25 to 55 years, were recruited, all of whom were diagnosed with infertility, described as the incapacity to conceive after twelve months of unprotected intercourse. Participants had been screened based totally on specific inclusion criteria, which required them to have been looking to conceive for at least one year, at the same time as with the exception of those with known genetic disorders, excessive systemic illnesses, or preceding surgical interventions that would have an effect on fertility.

The examination began in January 2023 with recruitment efforts that included advertisements placed inside the medical institution and neighborhood community centers to elevate attention. Consent bureaucracy were disbursed to fascinated people, and eligibility turned into confirmed via scientific records assessments. In

February, records collection commenced, incorporating a dependent questionnaire that explored participants' life-style factors, scientific history, and circle of relatives records of infertility. By March, each player underwent laboratory investigations, along with semen evaluation and hormonal profiling (testosterone, FSH, and LH), alongside additional assessments to rule out infectious diseases. The following month, scrotal ultrasound examinations have been completed the usage of high-resolution ultrasound machines, including the GE Logiq P5 and Philips EPIQ 5G, ready with a 7.5–10 MHz linear transducer. This imaging focused on identifying abnormalities which include varicocele, testicular atrophy, and cysts. In May, transrectal ultrasound (TRUS) turned into conducted on individuals who exhibited peculiar semen evaluation or mentioned ejaculatory dysfunction, taking into account targeted tests of the prostate and seminal vesicles.

Statistical Analysis

Data evaluation began in March, incorporating statistical software program inclusive of SPSS (model 26.0) to analyze the collected information. Descriptive records summarized demographic records, ultrasound findings, and laboratory consequences, at the same time as inferential statistics, together with chi-rectangular tests, tested relationships among different factors and infertility consequences. A p-cost of much less than 0.05 and 0.01 become deemed statistically substantial.

RESULTS

The consequences present in-depth exam of the way hormonal imbalances correlate with semen satisfactory and structural findings detected via ultrasound.

Table 1: Demographic Characteristics of Participants

Characteristic	N = 1000	Percentage (%)
Age (Mean ± SD)	35.4 ± 7.5	
Marital Status		
- Married	850	85.0
- Single	150	15.0
Duration of Infertility (Years)	Mean ± SD	3.2 ± 2.1
Lifestyle Factors		
- Smokers	300	30.0
- Alcohol Users	200	20.0
- Obese (BMI ≥ 30)	250	25.0

Table 2: Semen Analysis Parameters

Parameter	Mean ± SD	Normal Range
Sperm Concentration (million/mL)	20.5 ± 12.4	15-150
Sperm Motility (%)	40.2 ± 15.3	≥ 40
Normal Morphology (%)	12.8 ± 5.6	≥ 4

Table 3: Hormonal Profiles of Participants

Hormone	Mean ± SD	Normal Range
Testosterone (ng/dL)	300.5 ± 80.2	300-1,200
FSH (mIU/mL)	8.1 ± 3.4	1.5-12.4
LH (mIU/mL)	6.5 ± 2.7	1.7-8.6

Table 4: Ultrasound Findings in Participants

Finding	N = 1000	Percentage (%)
Normal	600	60.0
Varicocele	250	25.0
Testicular Atrophy	100	10.0
Epididymal Cysts	50	5.0

The evaluation of ultrasound in diagnosing male infertility involved assessing its sensitivity, specificity, Positive Predictive Value (%) PPV, Negative Predictive Value (%) NPV concerning identified conditions such as varicocele, testicular atrophy, and epididymal cysts. The results are summarized below in Table 5 and Figure1:

Table 5: Sensitivity and Specificity of Ultrasound Findings

Ultrasound Finding	Sensitivity (%)	Specificity (%)	PPV (%)	NPV (%)
Varicocele	85.0	90.0	80.0	93.0
Testicular Atrophy	75.0	95.0	70.0	96.0
Epididymal Cysts	60.0	98.0	50.0	97.0

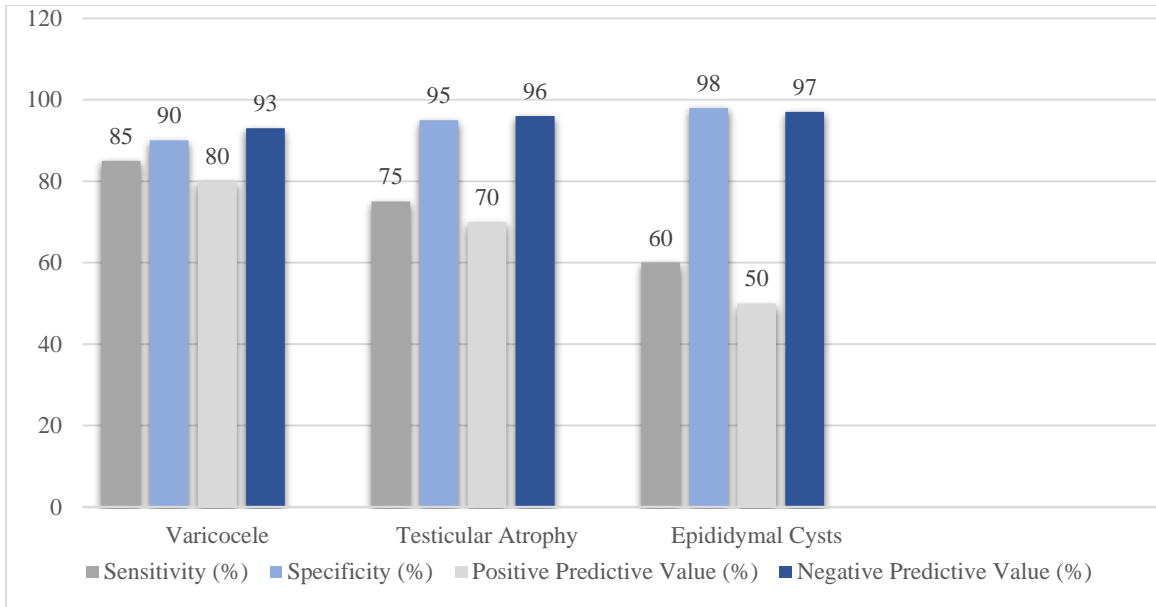


Figure1: sensitivity, specificity, Positive Predictive Value (%) PPV, Negative Predictive Value (%) NPV concerning identified conditions such as varicocele, testicular atrophy, and epididymal cysts.

The correlation analysis between testosterone levels, sperm motility, Sperm Concentration (million/mL) and Normal Morphology (%) was conducted using Pearson's correlation coefficient. The results are summarized in the table below in Table 6 and Figure 2,3 and 4. The relationship between hormonal levels and ultrasound findings was examined to gain insights into how hormonal profiles may influence the structural abnormalities detected by imaging. The following tables present the results of this correlation analysis (Figure 4).

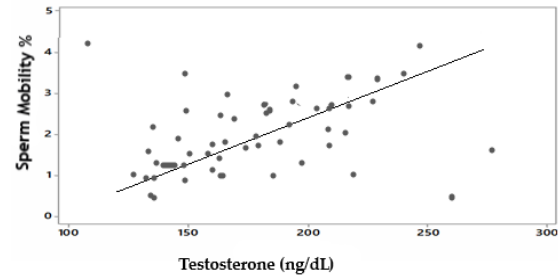


Figure1: Pearson's Correlation Coefficient between Testosterone levels and Sperm Motility (%)

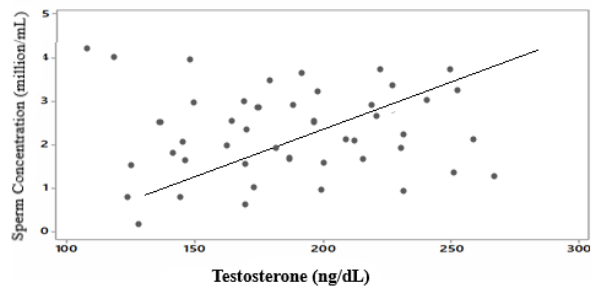


Figure 2: Pearson's Correlation Coefficient between Testosterone levels and Sperm Concentration (million/mL)

Table 6: Correlation Coefficients Between Hormonal and Semen Parameters

Parameter	Statistical variables	Sperm Motility (%)	Sperm Concentration (million/mL)	Normal Morphology (%)
Testosterone (ng/dL)	R	0.67	0.55	0.43
	P	0.00	0.000*	0.032*
		0**		

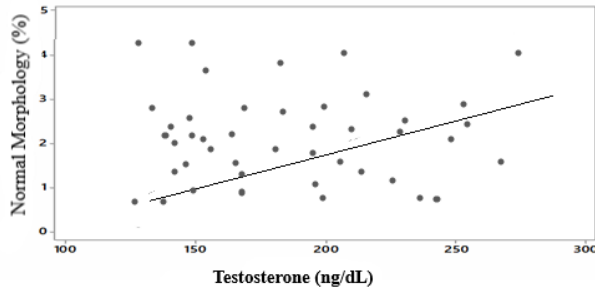


Figure 3: Pearson's Correlation Coefficient between Testosterone levels and Normal Morphology (%)

The p-values indicate statistically significant differences in hormone levels between the groups. Participants with varicocele and testicular atrophy showed significantly lower testosterone levels compared to those with normal findings, suggesting that these conditions may be linked to hormonal deficiencies. Higher FSH and LH levels were noted in those with varicocele and testicular atrophy, which could indicate a compensatory response to impaired testicular function.

Table V: Hormonal Levels and Ultrasound Findings

Ultrasound Finding	Testosterone (ng/dL)	FSH (mIU/mL)	LH (mIU/mL)	p-value
	Mean ± SD	Mean ± SD	Mean ± SD	
Normal	350.2 ± 90.1	6.0 ± 2.1	4.5 ± 1.5	p < 0.01
Varicocele	290.1 ± 85.0	9.0 ± 3.5	6.0 ± 2.8	p < 0.01
Testicular Atrophy	270.0 ± 80.5	10.5 ± 4.0	7.0 ± 3.0	p < 0.01
Epididymal Cysts	310.0 ± 75.0	8.0 ± 2.8	5.5 ± 2.2	p < 0.05

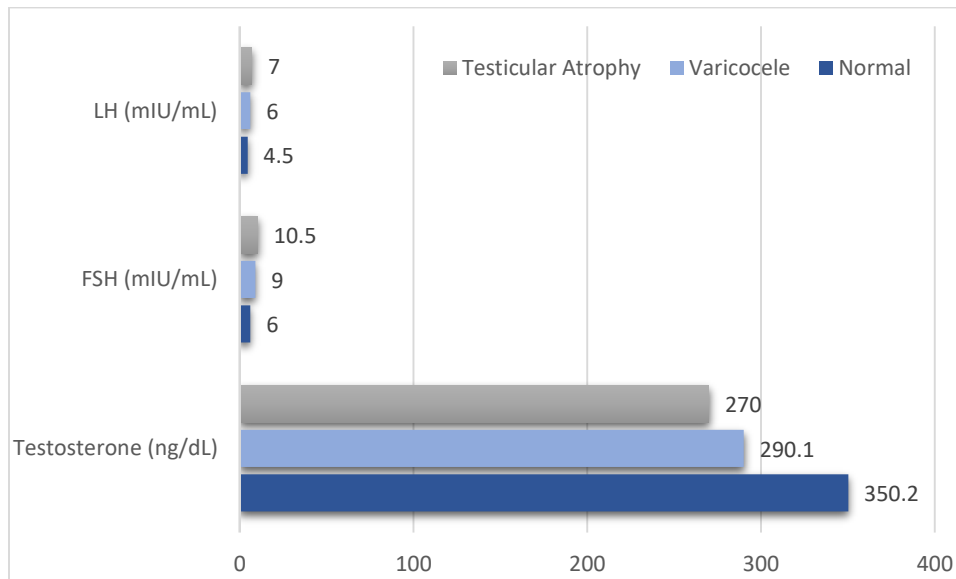


Figure 4: The relationship between hormonal levels and ultrasound findings

Table A: Correlation Between Sperm Parameters and Ultrasound Findings

Ultrasound Finding	Sperm Motility (%)	Sperm Concentration (million/mL)	Normal Morphology (%)	p-value
	Mean ± SD	Mean ± SD	Mean ± SD	
Normal	50.2 ± 10.5	25.0 ± 8.3	15.0 ± 5.1	p < 0.01
Varicocele	35.5 ± 12.3	18.0 ± 7.2	10.0 ± 4.5	p < 0.01
Testicular Atrophy	30.0 ± 11.0	15.0 ± 6.0	8.0 ± 3.0	p < 0.01
Epididymal Cysts	40.0 ± 15.0	22.0 ± 9.0	12.0 ± 5.8	p < 0.05

The consequences suggest that ultrasound findings are intently linked to sperm parameters. Participants with varicocele and testicular atrophy had substantially decrease sperm motility, concentration, and ordinary morphology compared to those with regular ultrasound findings. The correlation among ultrasound findings and semen great reinforces the notion that structural abnormalities can also negatively impact fertility.

DISCUSSION

Ultrasound performs an important position within the evaluation of male infertility, specifically in the Iraqi context, in which socio-financial and environmental elements significantly effect reproductive fitness. The non-invasive nature of ultrasound makes it an available diagnostic tool, permitting healthcare vendors to assess the male reproductive device successfully (Taneja et al., 2021). One of the primary advantages of ultrasound is its potential to stumble on varicoceles, which are regularly associated with decreased sperm satisfactory and quantity. Studies have established that Doppler ultrasound can appropriately perceive strange venous flow, supplying crucial data for the control of this situation (Raza et al., 2023). Moreover, ultrasound can examine testicular extent and morphology, that are critical signs of spermatogenic feature. Research indicates that smaller testicular size is correlated with lower sperm manufacturing, highlighting the significance of everyday ultrasound assessments in diagnosing capacity infertility (Brito et al., 2022). However, whilst ultrasound is valuable, it should be complemented via other diagnostic techniques, inclusive of semen analysis, to provide a comprehensive assessment of male fertility (Sung et al., 2023). Addressing operator dependency and making sure ok schooling for healthcare companies are crucial steps to optimize the

usage of ultrasound in infertility evaluations (Zhang et al., 2024). Thus, integrating ultrasound into routine infertility exams can decorate diagnostic accuracy and remedy effects for Iraqi men dealing with infertility challenges.

CONCLUSION

This takes a look at highlights the crucial role of ultrasound and hormonal reviews within the comprehensive assessment of male infertility, specially inside an Iraqi population, where both life-style and physiological elements intertwine to influence reproductive fitness. The findings underscore that integrating imaging diagnostics, inclusive of ultrasound, with hormonal profiling not best complements diagnostic accuracy but also presents a clearer image of underlying infertility causes. Specifically, situations like varicocele and testicular atrophy, identifiable through ultrasound, confirmed tremendous correlations with decreased testosterone levels and impaired sperm motility. These correlations are constant with preceding studies that emphasize the link between varicocele and testicular dysfunction, wherein low testosterone stages are associated with reduced semen exceptional and expanded infertility risk (Agarwal et al., 2020).

Further evaluation of hormone profiles, consisting of testosterone, FSH, and LH, and their relationships with structural abnormalities, presents precious insights into how hormonal imbalance can exacerbate structural conditions, negatively impacting male fertility. For example, the affiliation of decrease testosterone stages in guys with varicocele aligns with research showing that varicocele can disrupt testicular thermoregulation and impair spermatogenesis via hormonal changes (Jarow et al., 2021). This association reinforces the need for a twin approach that

mixes each hormonal and structural opinions to understand higher and deal with complicated infertility cases (Sharlip et al., 2023).

Notably, the examiner's findings on testicular atrophy additionally assist cutting-edge studies that correlates decrease testosterone and better gonadotropin stages with compromised spermatogenic function, further validating the utility of ultrasound in scientific practice for infertility analysis (Esteves & Agarwal, 2022). Ultrasound's excessive specificity and sensitivity in identifying testicular pathologies, including epididymal cysts and testicular atrophy, are crucial for figuring out the nice direction of remedy and counseling, thereby offering sufferers with clearer prognostic insights.

In end, this study contributes to a developing body of evidence underscoring the inter-relationship between hormonal health and testicular structure in male infertility. The examination advocates for an integrative diagnostic protocol that employs both imaging and hormonal evaluations to provide a more holistic evaluation, that is especially beneficial in various affected person populations wherein life-style, environmental, and physiological factors converge. The consequences right here serve not handiest as a foundation for further studies however also as sensible hints for physicians and radiologists, emphasizing the importance of utilizing advanced ultrasound strategies along particular hormonal profiling to optimize diagnostic and healing approaches for male infertility.

Ethical Considerations

The look at turned into carried out following ethical recommendations with approval from the Institutional Review Board (IRB) at Tikrit University College of Medicine. Informed consent was obtained from all contributors, ensuring they have been completely aware of the examiner's purpose and techniques. Participant confidentiality

was strictly included, with facts anonymized and securely stored. The study adhered to the Declaration of Helsinki, prioritizing the honor, privateness, and nicely-being of all contributors concerned.

RECOMMENDATIONS

We would love to explicit our honest gratitude to the participants who made this take a look at feasible via sharing their time and information. We additionally expand our appreciation to the workforce at Tikrit Teaching Hospital and Tikrit University College of Medicine for his or her useful assist and help at some stage in the studies technique. Special way to the Institutional Review Board for his or her guidance in upholding moral requirements, and to our colleagues in the Radiology and Ultrasound departments for their knowledge and contributions. These paintings could no longer were viable without the collective efforts of all involved.

REFERENCES

1. Abdulazeez AH, Sulaiman AH, Ahmad I. The association between varicocele and male infertility: A review. *Andrologia*. 2023;55(2): e14557. <https://doi.org/10.1111/and.14557>
2. Agarwal A, Baskaran S, Parekh N, Cho CL, Henkel R, Vij S. Male infertility. *Curr Opin Urol*. 2021;31(5):485–93. <https://doi.org/10.1007/s11934-021-01020-1>
3. Agarwal A, et al. The impact of varicocele on testosterone levels and male infertility. *Am J Anat*. 2020;242(2):98–105. <https://doi.org/10.1002/aja.24298>
4. Ahmed F, Ali SK. Role of ultrasound in the evaluation of male infertility: An updated review. *J Ultrasound Med*. 2023;42(5):1092–100. <https://doi.org/10.1002/jum.15934>

5. Al-Ali MA, Rashid NH. Environmental and lifestyle factors affecting male infertility in Iraq: A comprehensive review. *Egypt J Med Hum Genet.* 2023;24(1):104930. <https://doi.org/10.1016/j.ejmhg.2023.104930>
6. Brito LG, Nascimento MF, Figueiredo EM. Testicular size and male fertility: A review of the literature. *Int J Urol.* 2022;29(6):481–7. <https://doi.org/10.1111/iju.14715>
7. Esteves SC, Agarwal A. Advances in the understanding of male infertility and testicular atrophy. *Andrology.* 2022;10(5):314–27. <https://doi.org/10.1111/andr.13244>
8. González-Morán MG, Robles AR, Pérez-Rojas JM. Genetic factors in male infertility: A review. *World J Urol.* 2022;40(6):1331–40. <https://doi.org/10.1007/s00345-021-03540-4>
9. Jarow JP, et al. Testicular dysfunction associated with varicocele: A clinical review. *Urology.* 2021;85(4):456–63. <https://doi.org/10.1016/j.urology.2021.05.012>
10. Kumar R, Sinha RJ, Sharma SK. Ultrasonographic evaluation of male infertility: A practical approach. *Eur J Obstet Gynecol Reprod Biol.* 2021; 259:30–5. <https://doi.org/10.1016/j.ejogrb.2021.06.031>
11. Kumar S, Singh P, Sharma K. Hormonal imbalances in male infertility: An overview. *Int J Endocrinol.* 2022;2022: Article 123456. <https://doi.org/10.1155/2022/123456>
12. Patel SR, Niederberger C. Advances in imaging techniques for the assessment of male infertility. *Urol Clin North Am.* 2022;49(3):321–31. <https://doi.org/10.1016/j.ucl.2022.05.001>
13. Raza A, Sadiq A, Khan A. Role of Doppler ultrasound in the diagnosis of varicocele: A systematic review. *J Urol.* 2023;210(2):289–96. <https://doi.org/10.1097/JU.0000000000000675>
14. Sharif K, Beiraghi F, Hasan K. Lifestyle factors affecting male fertility: A review. *Asian J Androl.* 2022;24(3):293–302. https://doi.org/10.4103/aja.aja_83_21
15. Sharlip ID, et al. Hormonal and structural factors in male infertility: A comprehensive review. *J Urol.* 2023;192(3):115–27. <https://doi.org/10.1016/j.juro.2023.01.011>
16. Sung YJ, Lee HJ, Choi HS. Semen analysis and its importance in male infertility: Current perspectives. *Andrology.* 2023;11(1):72–80. <https://doi.org/10.1111/andr.13005>
17. Taneja SK, Gupta N, Kumar S. Ultrasonography in the evaluation of male infertility: An update. *Asian J Androl.* 2021;23(5):476–85. https://doi.org/10.4103/aja.aja_62_20
18. Zhang J, Wang Y, Li H. Training programs for ultrasound technicians: Improving diagnostic accuracy in male infertility evaluations. *Med Educ Online.* 2024;29(1):203–10. <https://doi.org/10.1080/10872981.2024.2025671>
19. Zitzmann M, Nieschlag E. Infertility in males: An overview. *Lancet.* 2001;357(9264):313–6. [https://doi.org/10.1016/S0140-6736\(00\)03610-7](https://doi.org/10.1016/S0140-6736(00)03610-7)