



ISSN: 1813-1638

The Medical Journal of Tikrit University

Available online at: www.mjotu.com

المجلات العلمية العراقية
IRAQI
Academic Scientific Journals

Haydar A. Jaafar ⁽¹⁾

Saad A. Mohammed ⁽²⁾

Samira A. Abdulla ⁽³⁾

(1), (2), (3) College of
Medicine, University of
Tikrit.
Iraq

Keywords:

Wisdom Teeth,
Young Patients ,
Dental treatment

ARTICLE INFO

Article history:

Received 01 May 2022

Accepted 29 May 2022

Available online 01 Sep 2022

The Medical Journal of Tikrit University The Medical Journal of Tikrit University The Medical Journal of Tikrit University The Medical Journal of Tikrit University The Medical Journal of Tikrit University

**Histology of Impacted Wisdom Teeth in Lower Jaw in
Young Patients Evaluated by 3D Imaging in Kirkuk City**

ABSTRACT

Introduction: Third molars, also known as wisdom teeth, is the most distal (posterior) of the three molars found in each quadrant of the human dentition. Tooth impaction is a pathological condition in which a tooth is unable or unwilling to erupt into its normal functioning position. Dental treatment can help with this issue.

Aim of study: The current study aims to describe the histology of wisdom teeth in the adult patients in Kirkuk city.

Materials and methods: Fifty patients with impacted wisdom teeth in lower jaw, with age ranging from (17–25) years were taken from dental specialized centers and from private clinics in Kirkuk city during the period from September 2021 to March 2022. An informed permission was obtained from the Kirkuk health directorate to perform this study.

All the patients with impaction and full dentition without missing teeth are included in age range , and above the age 25 years were excluded from this study. The patients with trauma, cysts and tumor are also excluded.

After taking a panoramic tomograph for patients, evaluation of the impacted wisdom teeth begin for all the cases which were 50 cases, firstly determine the number of wisdom teeth impacted in the lower arch either in left or right.

The 27 of patients (54 %) was female while the male was 23 patients (46%).

In all 50 samples there were 22% of cases which is 11 patient have one wisdom tooth impacted.

The 78% of cases which are 39 patients of the samples with two teeth impaction.

This study targets the patients who are between the ages (17-25) with impacted lower wisdom teeth living in the Kirkuk city, Iraq. The mean age, when diagnosed, was 21.84 years old. In this study, clinical data were collected from the specialized dental center in kirkuk , which has a policy of using DPT for all new patients with impacted 3M.

Anatomy of Dental Structure

A layer of enamel of varying thickness covers the crown of the tooth. It is almost entirely composed of apatite crystals with a calcium phosphate filling. Calcium phosphate is also primarily responsible for dentine hardness. The enamel layer crystals are all elongated and arranged with their ends toward the enamel's surface. Enamel is replaced around the root of the tooth by cementum (the cement), another bonelike material that holds the tooth firmly in the jaw socket. However, there is a layer of tissue called the periodontal membrane that exists between the bone of the jaw and the cementum layer and is in contact with the tissues of the gums and the pulp cavity. Incisor and canine teeth have a single root, premolars have two roots, and molars have three roots.

DOI: <http://dx.doi.org/10.25130/mjotu.28.2022.04>

*Corresponding author E mail : wisdom_tooth8@yahoo.com

Introduction:

Third molars, also known as wisdom teeth, are the most distal (posterior) of the three molars found in each quadrant of the human dentition. Tooth impaction is a pathological condition in which a tooth is unable or unwilling to erupt into its normal functioning position. Dental treatment can help with this issue. ⁽¹⁾

They usually appear between the ages of 17 and 25 years. Third molars should ideally erupt and be properly aligned with the rest of the teeth. However, these third molars are frequently misaligned, which can result in crowding of the teeth, damage to adjacent teeth, and, in rare cases, cystic pathology or root resorption. ⁽²⁾

Tooth impaction is one of the most common tooth position abnormalities. An impacted tooth (dens retens) is a tooth with a fully formed root that has completed development but is partially or completely covered by hard and/or soft tissues because it is outside of the physiological process of eruption. ⁽³⁾

The surgical removal of impacted wisdom teeth is a routine procedure in a dental surgery. In published studies, the prevalence of impacted teeth ranged from 6.9 to 76.6 percent. Third molars are the most commonly impacted teeth, especially in the mandible. They, along with the maxillary canine and mandibular second premolar, are among the most commonly impacted teeth. ⁽⁴⁾

There are two types of third molar impaction causes: general and local. ⁽⁵⁾ The phenomenon of impaction has become more prevalent in recent decades. This trend appears to be explained by an increasing level of hygiene, as well as less frequent tooth loss and the influence of a lack of physiological tooth attrition due to dietary changes. The genetic etiology of third molar impaction is important in the odontogenesis process. ⁽⁶⁾

Aim of the study

The current study aims to describe the architectural histology of wisdom teeth in the young patients in Kirkuk city.

Objective of the study

1- The objective of this meta-analysis was to evaluate the histology of third molar (3M) impaction in Kirkuk city in individuals ≥ 17 years, from both sexes, who had undergone oral three dimensional radiography.

2- To describe the histological structures of the impacted teeth.

Anatomy of Dental Structure

A layer of enamel of varying thickness covers the crown of the tooth. It is almost entirely composed of apatite crystals with a calcium phosphate filling. Calcium phosphate is also primarily responsible for dentine hardness. The enamel layer crystals are all elongated and arranged with their ends toward the enamel's surface. Enamel is replaced around the root of the tooth by cementum (the cement), another bonelike material that holds the tooth firmly in the jaw socket. However, there is a layer of tissue called the periodontal membrane that exists between the bone of the jaw and the cementum layer and is in contact with the tissues of the gums and the

pulp cavity. Incisor and canine teeth have a single root, premolars have two roots, and molars have three roots.⁽⁷⁾

Morphology-Histology of Teeth

The tooth consist of 2 Parts : Crown and Root:

1) Anatomical root: The portion of a tooth covered by cementum

2) Material and method

Fifty patients with impacted wisdom teeth in lower arch, with age ranging from (17–25) years were taken from dental specialized centers and from private clinics in Kirkuk city during the period from September 2021 to March 2022. An informed permission was obtained from the Kirkuk health directorate to perform this study.

All the patients with impaction are included in range age, and above the age 25 years were excluded from this study.

Extraction of the Impacted Wisdom Tooth.

The selected teeth were anesthetized with a dental syringe containing Lidocaine solution when nerve block and infiltration was

performed in order to study the histological components of the impacted wisdom tooth.

The extracted tooth was kept in a formalin-filled tube until it was transported to the laboratory for sectioning

Preparation of Decalcified Tooth Sections for Light Microscopy

1. Fixation of the Specimen.

Immediately after removal of the specimen, it was placed in a fixing solution in 10 percent neutral buffered formalin.

2. Decalcification

Teeth tissue contains very firm calcium deposits that, due to the difference in densities between calcium and paraffin, may not section properly with paraffin embedding. The material used for decalcification in this study is Hydrochloric acid for 5 days with 37%.

3. Dehydration of the Specimen.

Since the specimen must be completely infiltrated with the paraffin that was embedded in and infiltrated with some substance that is miscible with paraffin.

4. Clearing of the Specimen.

The clearing was done to remove the alcohol from the tissue while also allowing fluid that easily mixes with paraffin to permeate.

The results:

After taking a cone beam computed tomography for patient, evaluation of the impacted wisdom teeth begin for all the cases which were 50 cases, firstly determine the age of the samples for the females range from 17 to 24 and for the males range from 18 to 25. The mean age for all the samples was 21.84 .

Secondly determine the number of wisdom teeth impacted in the lower arch either in left or right.

The 27 of patients (54 %) was female while the male was 23 patients (46%).

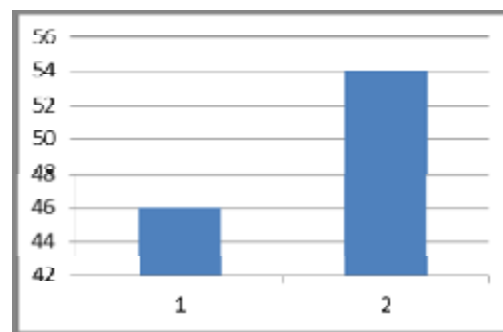


Figure 1 the percentage of the patients(1 male, 2 female).

The histological study done by

sectioning with ground and decalcified section

and different planes as the following:

1. longitudinal mesiodistal section, viewed from the Buccal view in posterior teeth.(figure 2)
2. horizontal sections through the crown, section viewed from Occlusal view.
3. horizontal sections through the roots in the cervical line.
4. horizontal section through the roots in the mid of the roots.

After studying the tooth under microscope there was the following structures:

- 1.Enamel
2. Dentine
3. Pulp (see the figure which is longitudinal section of a tooth).

1.The Enamel.

Only ground sections of enamel were examined under the light microscope.

1. The Enamel Consist of the Following Structures : (figure 3)

1. Enamel Rods
2. Retzius' Striae
3. Enamel Lamellae
4. Tufts Enamel
5. Enamel
6. Enamel with Gnarled

7. Hunter–Schreger Bands

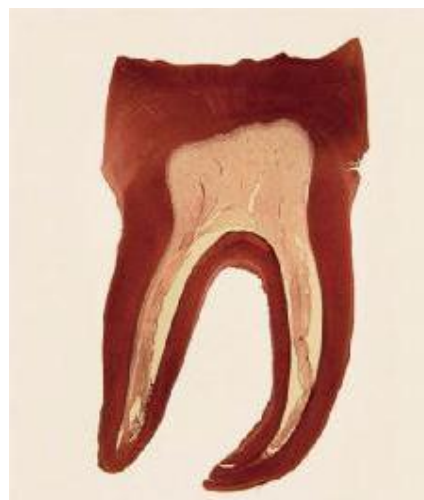

Figure (2): longitudinal section of tooth(H&E. X4)




Figure (3): a section of enamel. A. dentino-enamel junction B. enamel lamella C. dentine (H&E X40).

2. The Dentin.

Dentin is a mineralized tissue that forms the bulk of the tooth.

Dentin Classification: Primary and Secondary Dentin.(figure 4)

Dentinoenamel Junction

The junction between dentin and

enamel, termed dentinoenamel junction, was scalloped.

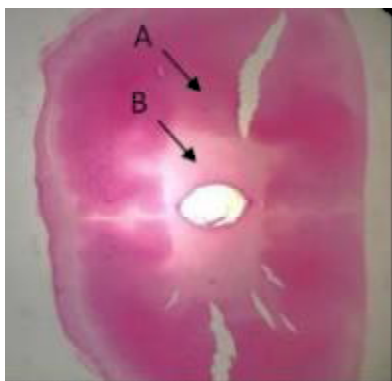


Figure (4): The primary & secondary dentine. A. primary dentine B. secondary dentine (H&E. X4).

3. The Dental Pulp

Pulp was the only soft tissue component of teeth, found in the center within a space in the dentin called pulp cavity. (figure 5)

4. Zones of the Pulp.

There were four recognizable areas or zones in the pulp. Starting from the periphery (dentinal side), these were:

1. The odontogenic
 2. Cell-free zone
 3. The cell-rich zone
 4. The pulp core
4. The Cementum.

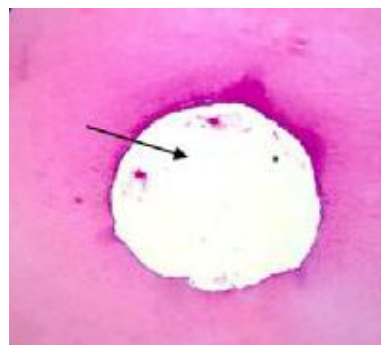


Figure (5): The dental pulp (cross section H&E X4).

The Cementum:

Cementum was a thin mineralized tissue that covered the roots of teeth. It served as an attachment for the periodontal ligament fibers, thereby helping to hold the teeth in their sockets. It was avascular and noninnervated. The thickness of cementum gradually increased from the cervical line to the apical region. It could be studied using ground sections or decalcified sections.(figure 6)




Figure (6): Longitudinal section of the cementum (H&E X4).

Discussion:

This study targets the patients between the ages (17-25) with impacted lower wisdom teeth living in the Kirkuk city, Iraq. The mean age, when diagnosed, was 21.84 years old. In this study, clinical data were collected from the specialized dental center in kirkuk , which has a policy of using DPT for all new patients with impacted 3M.

The present description is in agreement with description of Som PM et al.⁽⁸⁾

That stated dentin, like enamel, was avascular, and its substructure was a collection of minute channels called dentinal tubules that carry cytoplasmic extensions of the progenitor odontoblasts and run the length of the dentin thickness. The main component within the dentinal tubules was the odontoblastic processes, which may extend to the dentinoenamel junction in some cases.⁽⁹⁾

While linear defects were thought to be nonspecific stress markers, this agrees

with Mcgrath K et al.⁽¹⁰⁾

In addition, incremental lines might be seen in the dentin. Von Ebner's lines were daily short-period lines in the dentin, this is the same finding in⁽¹¹⁾

From the pulp, a network of channels radiated outward toward the Dentino-Enamel Junction (DEJ) and cementum. The density and diameter of tubules were lowest at the DEJ and rise as they got closer to the pulp, this agrees with Arola et al.⁽¹²⁾

Coronal dentin cracks tended to be perpendicular to the tubules, this agrees with Maghami et al.⁽¹³⁾

Ameloblast differentiation and secretion was not consistent, which produced incremental markings in the form of cross striations and Retzius lines. Cross striations occurred at a rate that corresponded to a circadian rhythm. This agrees with Xie et al. and Papakyrikos et al.^(14,15)

Studies showing the bilateral and unilateral occurrences of impacted third molars are very rare. Dachi and Howells⁽¹⁶⁾ found that unilateral and

bilateral impactions of third molars occurred with almost equal frequency. In our study, we found that the frequency of bilateral impaction is a little higher than unilateral impaction. Quek et al.⁽¹⁷⁾ also mentioned that bilateral occurrence of third molars was more common than unilateral impactions in their study.

Conclusion & Recommendation:

No histological difference in wisdom teeth structure between male and female.

Many pathologies were associated with impaction of wisdom teeth.

Recommendation

Farther study to include impaction of maxilla in the study plus the study of mandibular impaction.

Increase the range of age to study the eruption of wisdom teeth.

Extend the range of age in the future study to include beyond than 25 years old to see the impaction in older patients.

Extend the study to include upper jaw in addition to lower jaw to see the anatomical positions of the impacted wisdom teeth.

Widening the study to include the causes of impaction in both male and female, and find best ways to avoid the impaction that is related to physiological causes of impaction.

References:

1. Kumar V.R, Yadav P, Kahsu E, Girkar, F.; Chakraborty, R. Prevalence and Pattern of Mandibular Third Molar Impaction in Eritrean Population: A Retrospective Study. *J. Contemp. Dent. Pract.* 2017, (18) 100–106
2. Al-Dajani, M.; Abouonq, A.O.; Almohammadi, T.; Alruwaili, M.K.; Alswilem, R.O.; Ibrahim, A.A.; Alzoubi, A. Cohort Study of the Patterns of Third Molar Impaction in Panoramic Radiographs in Saudi Population. *Open Dent. J.* 2017, 11, 648–660.
3. Khouri, C., Aoun G., Khouri C. et al. Evaluation of Third Molar Impaction Distribution and Patterns in a Sample of Lebanese Population. *J. Maxillofac.*

- Oral Surg. (2020).
4. Wazir, S.; Khan, M.; Ashfaq, M.; Manzoor, S. Evaluation of Third Molar Impaction Distribution and Patterns in a Sample of Lebanese Population. *Pak. Oral Dental, J.* 2017; 37: 547–50.
 5. 11. Arabion, H., Gholami, M., Dehghan, H., Khalife, H. Prevalence of impacted teeth among young adults: a retrospective radiographic study. *J. Dental Mater. Tech.* 6 (3), 2017.p: 131–137.
 6. Al-Anqudi, S.M.; Al-Sudairy, S.; Al-Hosni, A.; Al-Maniri, A. Prevalence and Pattern of Third Molar Impaction: A retrospective study of radiographs in Oman. *Sultan. Qaboos. Univ. Med. J.* 2014, 14, 388–392.
 7. Singh, Rohit¹; Devanna, Raghu²; Tenglikar, Pavan³; Gautam, Ashesh⁴; Anubhuti, ⁵; Kumari, Priyanka⁶ Evaluation of mandibular third molar position as a risk factor for pericoronitis, *Journal of Family Medicine and Primary Care*: March 2020; Volume 9, Issue 3 : p 1599-1602.
 8. Som PM, Miletich I. Review of the embryology of the teeth. *Neurographics* 2018 Oct 1;8(5):369-93.
 9. Vág J, Freedman G, Szabó E, Románszky L, Berkei G. Cervical tooth anatomy considerations for prefabricated anatomic healing abutment design: A mathematical formulation. *J Prosthet Dent* 2021 Jan 16.
 10. Mcgrath K, Limmer LS, Lockey AL, Guatelli-Steinberg D, Reid DJ, Witzel C, et al. 3D enamel profilometry reveals faster growth but similar stress severity in Neanderthal versus Homo sapiens teeth. *Sci Rep* 2021 Jan;11.
 11. O'Hara M. Applying standard perikymata profiles to Pongo pygmaeus canines to estimate perikymata counts between linear enamel hypoplasias. *Am J Phys Anthropol.* 2017;163(1):213-22.
 12. Arola DD, Gao S, Zhang H, Masri R. The tooth: its structure and properties. *Dent Clin North Am.* 2017;61(4):651-68.
 13. Maghami E, Pejman R, Najafi AR. Fracture micromechanics of human dentin: A microscale numerical model. *J Mech Behav Biomed Mater.*

2021;114(1):104-171.

14. Xie Y, Tang Q, Yu S, Zheng W, Chen G, Huang X, et al. Orthodontic force– induced BMAL1 in PDLCs is a vital osteoclastic activator. *Dent Res J* 2021;3:53-57.

15. Papakyrikos AM, Arora M, Austin C, Boughner JC, Capellini TD, Dingwall HL, et al. Biological clocks and incremental growth line formation in dentine. *J Anat* 2020;237(2):367-78.

16. Dachi SF, Howell FV. A survey of

3, 874 routine full-month radiographs.

II. A study of impacted teeth. *Oral Surg Oral Med Oral Pathol.* 1961 Oct;14:1165-9. doi: 10.1016/0030-4220(61)90204-3. PMID: 13883048.

17. Kachhara S, Nallaswamy D, Ganapathy D, Ariga P. Comparison of the CBCT, CT, 3D printing, and CAD-CAM Milling options for the most accurate root form duplication required for the root analogue implant (RAI) protocol. *JIAOMR.* 2021;33(2):141.