



ISSN: 1813-1638

**The Medical Journal of Tikrit University**

Available online at: [www.mjotu.com](http://www.mjotu.com)

**MJTU**

The Medical Journal of  
Tikrit University

## Success Rate of Transcanalicular Diode LASER –Assisted Dacryocystorhinostomy

Bassam M. S. AL-Abachi <sup>(1)</sup>; Ghassan M. Ahmed <sup>(2)</sup>; Huda A. Mustafa <sup>(3)</sup>

<sup>(1)</sup> FRCS Opth. Glasgow. Specialized center of ophthalmology in Mosul City; <sup>(2)</sup> MB.Ch.B-C.A.B.M.S; <sup>(3)</sup> DRMR Rheumatology

### Keywords:

diode laser, nasolacrimal duct, epiphora, dacryocystitis

### ARTICLE INFO

#### Article history:

Received 12 Sep 2022  
Accepted 11 Dec 2022  
Available online 31 Jun 2023

© 2023 THIS IS AN OPEN ACCESS  
ARTICLE UNDER THE CC BY  
LICENSE

<http://tikrit-medicine.tripod.com/id10.html>



Citation: Bassam M. S. AL-Abachi;  
Ghassan M. Ahmed; Huda A. Mustafa.  
Success Rate of Transcanalicular  
Diode LASER –Assisted  
Dacryocystorhinostomy. The Medical  
Journal of Tikrit University (2023) 29  
(1): 166-175

DOI: <http://dx.doi.org/10.25130/mjotu.29.1.10>

### ABSTRACT

#### Objective:

To study the percentage of success rate of transcanalicular diode LASER assisted Dacryocystorhinostomy TC-DLA-DCR in case of acquired nasolacrimal duct obstruction(NLDO).

#### Method:

A thin fiber of 360 micron diameter with 918 nm diode LASER has a very high energy at LASER tip which help in vaporization of bone and soft tissue at low LASER power .

In our technique a thin fibro-optic pass through dilated upper or lower punctum to the lacrimal sac and aiming beam seen through a rigid nasal endoscope attached to a screen and once the proper position is reached the laser is fired to ablate the bone and nasal mucosa and appropriate osteotomy is done.

#### Results:

Seventy five patients (26male and 49 female)were followed from Jan. 2017 to Aug 2022 with bicanalicular intubation .follow up show absence of epiphora and a patent nasolacrimal duct on irrigation 73 out of 75 patients. 3out 73 patients had epiphora despite a patent NLD on irrigation.

#### Conclusion:

980nm diode laser through 360micrometer fiber is very effective in bone penetration and ablation.It minimally invasive, quick surgery, can be done under local anesthesia and in patient with coagulopathy and have a high success rate.

## Introduction:

Commonly seen in ophthalmological practice is primary acquired nasolacrimal canal obstruction, which has been defined as presenting with persistent epiphora and with or without dacryocystitis(1). A bone ostium is used as a direct conduit for anastomosis between the lacrimal sac and the nasal cavity during a dacryocystorhinostomy. The dacryocystorhinostomy may be performed using a variety of different surgical techniques. These include endomechanical dacryocystorhinostomy, external dacryocystorhinostomy, endonasal laser dacryocystorhinostomy, and transcanalicular laser-assisted dacryocystorhinostomy. The dacryocystorhinostomy aided by a diode laser has number of distinct benefits over the conventional dacryocystorhinostomy.[2] Over the past ten years, endocanalicular and endonasal surgical treatments have grown in popularity thanks to improvements in laser and endoscopic methods. The benefits of less invasive surgical techniques, like external dacryocystorhinostomy, include quick

recovery times, cosmesis, fewer morbidity risks, and no damage to the orbicularis oculi pump mechanism(3).

The dacryocystorhinostomy utilizing the traditional external method as a treatment for the lachrymal obstruction has been indicated in 1904 by Toti; later modifications were added in 1921 by Dupuy-Dutemps and Bourget, who have described suturing mucosal flaps (4).

Killian published the first intranasal method in 1889, and Caldwell performed the first endoscopic dacryocystorhinostomy in 1893.

However, both procedures were quickly abandoned because of challenging visualization and severe complications(5). The endoscopic technique was resurrected thanks to the development of new technologies utilized in endoscopic sinus surgery, which allows for improved visualization(6).

The endocanalicular technique, initially reported in 1963 by Jack Ois the final development of a less traumatic dacryocystorhinostomy. In this method, a probe has been inserted through lower lacrimal punctum down canaliculus into

lacrimal sac, following an anatomical pattern of the tear outflow(7).

Osteotomy has been carried out using either a mechanical drill or laser energy delivered by optic fiber placed into the prue(8).

Eloy et al.(2000) and Fernandez et al.(2004) were the first to disclose using a diode laser for Endolaser-dacryocystorhinostomy (EL-DCR) (9,10).

It is possible to advance through the various tissues with good coagulation and with no distance thermal effect thanks to the diode lasers' 980 nm wavelength, which has good ratio between the penetration and the minimal injury from the beam dispersion compared to other laser types. However, progress should be made in terms of contact with body structures(11-12).

Transcanalicular laser-assisted dacryocystorhinostomy involves precise tissue removal by ablation, shorter operating time, less blood loss, repeatability, no external scarring, preservation of ligaments and muscles of internal canthus, and preservation of

lacrimal pump function. It may be carried out under the local anesthesia(13).

### **Method:**

With retrospective non-comparative case series study of 75 patient with nasolacrimal duct obstruction were undergone diode laser assisted transcanalicular dacryocystorhinostomy (DLA-TC-DCR) between Jan,2017- Aug 2022. Patient with primary nasolacrimal duct obstruction were included, while exclusion criteria include acute dacryocystitis , nasal polyp and trauma.

Patients with lacrimation were examined with slit lamp & looking for the punctum of the lower and upper lid (punctum atresia) pull the lower lid away from the globe & look for the lid to go back & if it delayed(lower lid laxity).

Examine the lid for signs of blepharitis. Syringing and lacrimal irrigation were done & patients with NLDO were selected for the operation.

Success is determined by absent lacrimation & patent to irrigation.

Seventy tow cases were done under GA & 3 cases with local anesthesia according to the patient preferences and clinical

indication. Nasal packing 20 min prior to surgery with lidocaine solution 2% with adrenaline 1:100000. With systemic sedation, a mixture of lidocaine and epinephrine was injected in to the nasal mucosa .using Nittleship dilator to dilate both upper and lower punctum and use of Bowman probe to feel hard stop or soft stop.

I did a minor modification by using very fine fibroptic & passed it through spinal cannula. I did tapering of the sharp edge of the cannula after cutting part of it & was introduced in to the lower punctum & then in to the canalicule & entered to the sac.

My collogue the otolaryngologist using 0 degree rigid nasal endoscope attached to the monitor and decrease the light of the room search for green aiming beam and once the aiming beam in correct position do firing the laser using 10W in 918 nm to make an opening in the mucosa & bone & make another one few mm away & connect both osteum to make a big one about 10 mm, irrigation done and intubation with silicone tube. One from lower punctum and other side from upper punctum & both pass through the osteum

& both tide and use 3/0 vicryl thread both silicone tube not too tight & not too loose be careful of both puncta. Nasal packing with mitomycine solution 2% for 20 min(14) ,postoperative painkiller & systemic antibiotics & topical steroid and antibiotic eye drops were given four times daily together with nasal wash using sodium bicarbonate 3% twice daily and topical cyclosporine eye drops QID for tow weeks.

Follow up visit will be first postoperative day & after one week, one month and three months. After 3 months silicon tube will be removed.

Informed consent: Verbal informed consent was obtained from all subjects included.

Ethical approval: All procedures were conducted in compliance with the tenets of the Declaration of Helsinki .

### **Results:**

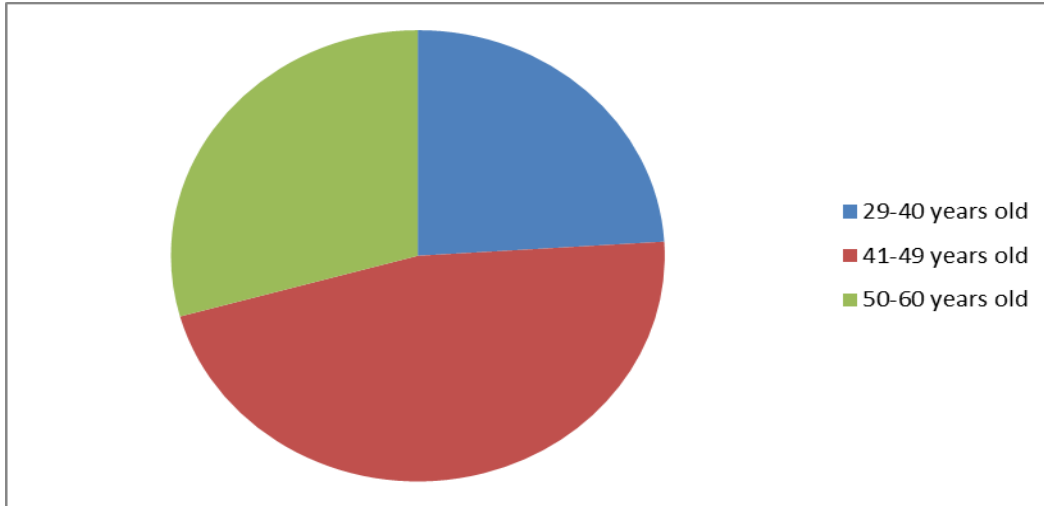
DLA-TC-DCR treated seventy-five patients;of them 18 patients aged between (29-40) years & 35 patients were aged (41-49) years and 22 patients aged (50-60) years old. As shown in figure (1) & (2)

Of these 26 were male and 49 were female as shown in figure (3) &(4).

Fifty four patients had left eye & 21 of them were right eye as shown in figure (5)

Two patients had recurrent dacryocystitis & obstruction & 3 patients had functional epiphora with successful syringing.

So the success rate of DLA-TC-DCR is

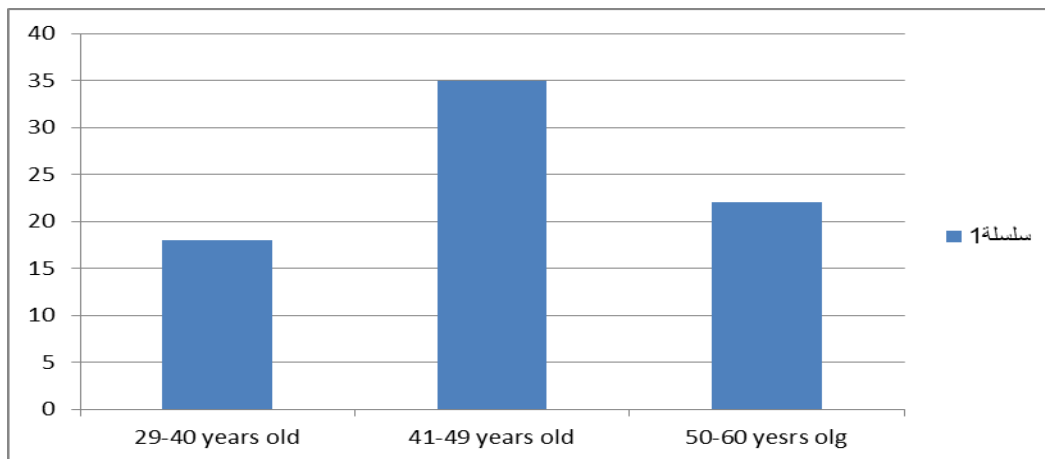


97.34% as shown in figure( 6 ).

Figure (1)

Age distribution of patient.

Number of patients



Age(year) Figure (2) Number of patients

Age distribution of patient.

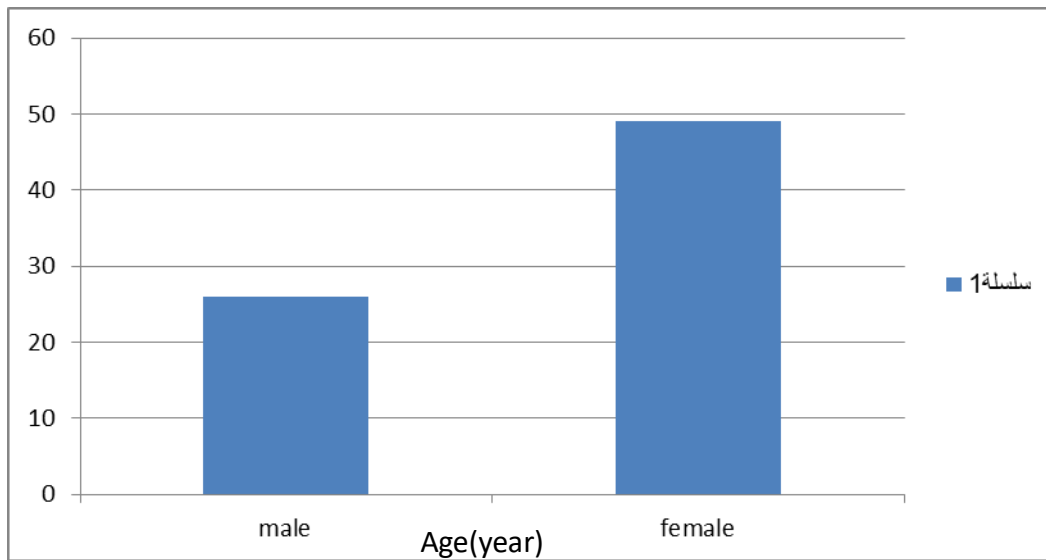


Figure (3) Gender distribution of patient.

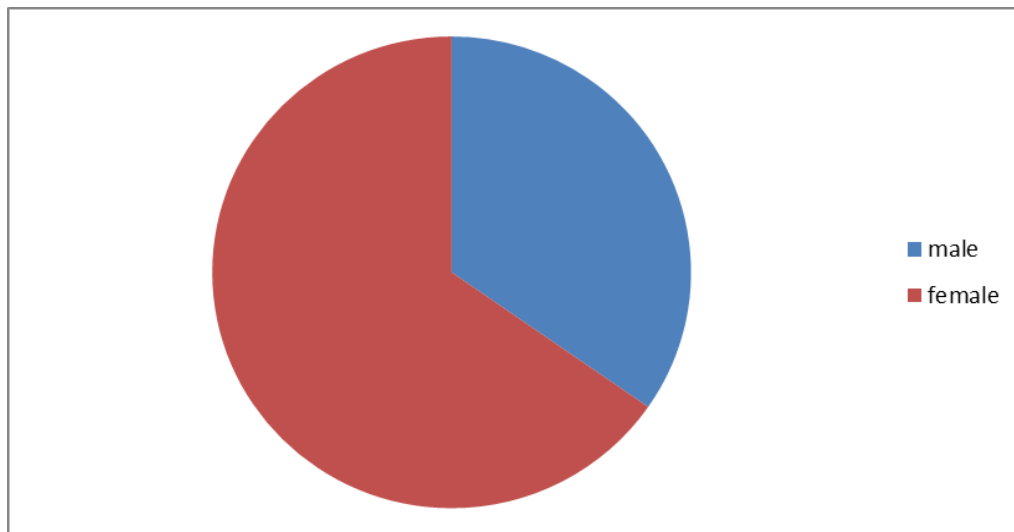


Figure (4) Gender distribution of patient.

Number of patients

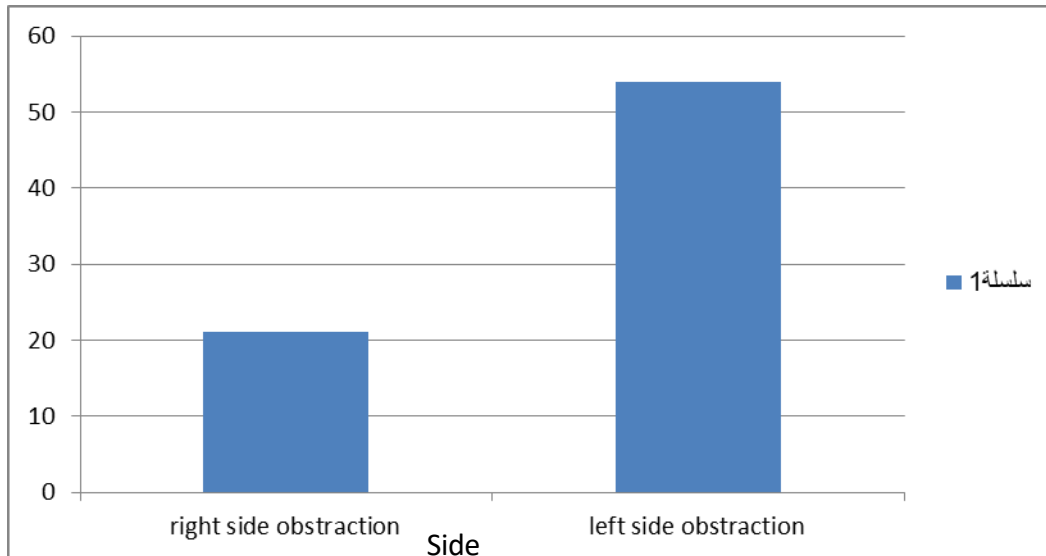


Figure (5) Side distribution of patient.

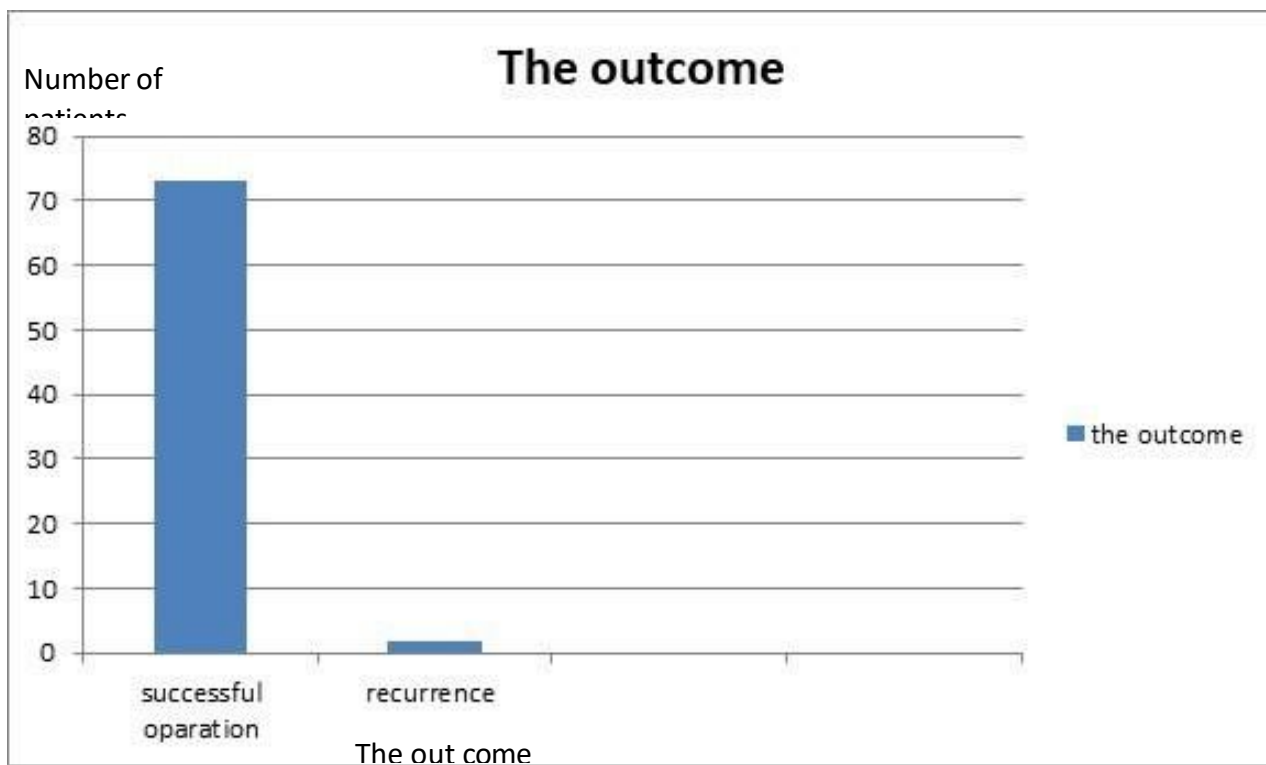


Figure (6) The outcome.

### **Discussion:**

DLA-TC-DCR is very effective and have high success rate 97% and fast procedure and can be done under local anesthesia & in patient with coagulopathy.[15]

This procedure has fast learning curve with minimal trauma to surrounding tissue & no skin incision is needed and no scar with fast recovery & is done as an outpatient procedure.

We are aiming for osteotomy of 10mm size.

In our study we do intubation of upper and lower canaliculi routinely for 3 months & can be removed by cutting the loop near the medial canthus & remove the tube from the nose.

Laser DCR can be used in failed external DCR where only removal of thin membrane can be easily penetrated with diode laser also can be used in acute dacryocystitis [16]

But in this study we make acute dacryocystitis as exclusion criteria.

Contraindicated in Wegener granulomatosis & lacrimal cyst tumor and lacrimal sac pathology.

### **Causes of NLDO**

- ❖ Most common cause of NLDO is idiopathic
- ❖ Nasoorbital trauma including nasal sinus surgery .
- ❖ Granulomatous disease (granulomatosis with polyangitis)& sarcoidosis .
- ❖ Infiltration with nasopharyngeal tumor.

### **Conclusion:**

980nm diode laser assisted transcanalicular dacryocystitis can be done under local anesthesia & in patient with blood dyscrasia and very safe and effective, and has a high rate of success.



**References:**

1. Tarbet KJ, Custer PL. External dacryocystorhinostomy. Surgical success, patient satisfaction, and economic cost. *Ophthalmology*. 1995;102(7):1065-70. Comment in: *Ophthalmology*. 1996;103(2):200.
2. Plaza G, Beteré F, Nogueira A. Transcanalicular dacryocystorhinostomy with diode laser: Long-term results. *Ophthalmol Plast Reconstr Surg* 2007;23:179-82.
3. Athanasiov PA, Prabhakaran VC, Mannor G, Woog JJ, Selva D. Transcanalicular approach to adult lacrimal duct obstruction: a review of instruments and methods. *Ophthalmic Surg Lasers Imaging*. 2009;40(2):149-59
4. López de Letona C. La dacriocistorrinostomía en España (1914). *Arch Soc Esp Oftalmol*. 2001;10.
5. Mahmood S, Sadiq A. A short history of lacrimal surgery. *CME Journal Ophthalmology* 2001;5:76-8. Available from: <http://www.rila.co.uk/issues/full/download/60b91149a8390c2ba2c9033c405910ee793220.pdf>. [last accessed on 2007 Dec 29].
6. Kennedy DW. Functional Endoscopic Sinus Surgery: Technique. *Arch Otolaringol* 1985;111:643-9.
7. Jack MK. Dacryocystorhinostomy: Description of A transcanal method. *Am J ophthalmol*. 1963;56:974-7.
8. Reifler DM. Results of KTP laser-assisted dacryocystorhinostomy. *Ophthalmolplast. Reconst. Surg*. 1993;9:231-6.
9. Eloy P, Trussart C, Jouzdani E, Collet S, Rombaux P, Bertrand B. Transcanalicular diode laser assisted dacryocystorhinostomy. *Acta Otorhinolaryngol Belg* 2000;54:157-63.
10. Alapón Fernández FJ, Alapón Fernández MA, Martínez Fernández A, Cardenas Lara M. Transcanalicular dacryocystorhinostomy technique using diode laser [in Spanish]. *Arch Soc Esp Oftalmol* 2004;79:325-30.
11. Alañón Fernández FJ, Alañón Fernández MA, Martínez Fernández A, Cardenas Lara M. Dacriocistorrinostomía transcanalicular con láser diodo. *Arch Soc Esp Oftalmol*. 2004;79:325-30.
12. Murube E, Murube J. Nuevas tecnologías en la práctica médica. El láser en oftalmología. *Jano*. 1997;53:85-97.
13. Dalez D, Lemagne JM. Transcanalicular dacryocystorhinostomy by pulse holmium-YAG laser. *Bull Soc Belge Ophtalmol* 1996;263:139-40.

14. Slam MR, WadudSA, Akhanda AH, Rahman MS, Habibullah M, Kabir MS, et al. Outcome of Transcanalicular Endolaser and External Dacryocystorhinostomy in Chronic Dacryocystitis. *Mymensingh Med J.* 2018;27(4):673-678.

15., Drnovsek-Olup B, Beltram M. Transcanalicular diode laser-assisted dacryocystorhinostomy. *Indian J Ophthalmol*

doi: 10.4103/0301-4738.62646 217-213:)3(58 ;2010

16. Koch, K.R, Cursiefen, Cu Heindt, L.M. Transcanalicular Laser

D. acryocystorhinostomy: One-Year-Experience in the Treatment of Acquired Nasolacrimal Duct Obstructions. *Klin Monbl Augenheilked* 2016-233(2):182-

186. doi: 10.1055.